

Original Article

Effect of water pollution in Sevastopol bays (Black Sea) on histopathological and oxidative stress biomarkers of black scorpionfish *Scorpaena porcus*

Irina Ivanovna Rudneva^{*1}, Alexandr Germanovich Selyukov^{2,3}, Valentin Grigor'evich Shaida⁴, Innokenty Sergeevich Nekrasov^{2,3}

¹Marine Hydrophysical Institute, Russian Academy of Sciences, Kapitanskaya st., 2, Sevastopol, 229011, Russian Federation.

²Institute of Biology, University of Tyumen, Pirogov st., 3, Tyumen, 625043, Russian Federation.

³AquaBioSafe Laboratory, University of Tyumen, Lenin st., 23, Tyumen, 625003, Russian Federation.

⁴Ecoservice-A, Moscow, Verhnyaya Krasnoselskaya st, 17A, Building 17A, of. 8 107140, Russian Federation.

Abstract: In two of the bays, Streletsкая Bay and Balaklavskaya Bay (Sevastopol, Black Sea), historically affected by various kinds of anthropogenic activity, we assessed environmental pollution using liver, gonads, and gill histopathological indicators and antioxidant biomarkers in black scorpionfish *Scorpaena porcus* L. The results show several differences in histological alterations across the liver, gills, and gonads, as well as in blood antioxidant enzymes (superoxide dismutase, peroxidase, catalase, and glutathione reductase) among fish from the study areas. Gonads of all females examined from both bays showed atresia of vitellogenic oocytes. Histological analysis of the fish gills has demonstrated hyperplasia of the respiratory lamellae, which could significantly decrease the interlamellar length. In both areas, the most prominent histological changes observed in liver tissue were lipid alterations in hepatocytes. In several females, degeneration of the hepatic parenchyma was also found. These findings indicate that living conditions at both sites were suboptimal for the examined species, with soluble toxicants potentially contributing to the observed tissue alterations. Analyses of histological alterations in the tissues tested and of antioxidant enzyme activities, such as peroxidase and superoxide dismutase, in fish blood may reflect varying levels of pollution across bays, with higher levels in Streletsкая Bay than in Balaklavskaya Bay. The biomarkers examined could be used in future monitoring of water quality in the Sevastopol bays.

Article history:

Received 16 January 2025

Accepted 27 November 2025

Available online 25 December 2025

Keywords:

Liver

Gonad

Gill

Blood antioxidants

Environmental analysis

4

Introduction

Marine ecosystems and aquatic organisms are continuously threatened by anthropogenic contamination, especially in coastal areas. Chemical pollutants, such as pesticides, polycyclic aromatic hydrocarbons (PAHs), pharmaceuticals, heavy metals, plastics, nanoparticles, and emerging contaminants, impact marine organisms (Monfared et al., 2015; Dane and Şişman, 2020a, b; Guerrera et al., 2021; Kadim and Risjani, 2022; Orso et al., 2023). Long-term exposure to pollutants, even in low concentrations, worsens organisms' living conditions and health. Because humans commonly consume aquatic organisms, pollutant accumulation in these organisms poses a risk to human health, and such seafood is not suitable for human consumption

(Hussain et al., 2021; Orso et al., 2023).

Various human activities, namely industry, agriculture, fisheries, mariculture, tourism, petroleum, and gas production, along with domestic infrastructure, maritime transport, and the navy, impact the Black Sea ecosystem, especially its coastal areas (Ulas, 2022). The current structure and the pollution of the Sevastopol bays have many social, economic, and natural causes. The bays are subject to contamination due to their geographic location and surrounding areas. Significant anthropogenic impacts from municipal infrastructure, maritime transport, and industrial enterprises characterize Streletsкая and Balaklavskaya bays. Therefore, they allow us to understand the main trends in anthropogenic impacts on fish health and to define biomarkers for stress

*Correspondence: Irina Rudneva
E-mail: svg-41@mail.ru

assessment under current conditions.

At present, elevated levels of anthropogenic pollutants, along with natural contaminants from geological activities, erosion, atmospheric precipitation, and transboundary transfer, also enter water bodies. Moreover, although water body pollution levels do not show marked differences among sites, ecosystems, or aquatic organisms, their health may differ significantly. Therefore, the use of aquatic organism biomarkers gives support through the responses of biological effects to the analysis of the living conditions in water bodies and can contribute to the development of effective methods for analyzing the quality of the aquatic environment (Ballesteros et al., 2017; Santos et al., 2023; Phadmacanty et al., 2023).

Fish are indicator organisms in aquatic ecosystems because they live in direct contact with their immediate environment and are therefore highly sensitive to aquatic pollutants. Contaminants accumulated in tissues induce oxidative stress, damage to organ structure and function, and disruption of normal metabolism, reproduction, development, and adaptability, resulting in dysfunction. These alterations induce the pathologies and morphological anomalies (Dane and Şişman, 2021; 2023; Zaman et al., 2023; Rohany, 2023). Fish bioindicators can be used to analyze general responses and toxic effects of chemicals and pathogens that interact within complex natural environments (Santos et al., 2022a, b; Matrodzadeh et al., 2023).

Various stressors in marine environments necessitate the selection of biomarkers to assess their adverse effects on aquatic organisms (Montenegro et al., 2022; Bhat et al., 2023; Sayed et al., 2023). Biochemical and physiological alterations are good indicators of pollutant effects at the molecular and cellular levels. Among them, the antioxidant and immunological defense mechanisms of aquatic organisms can serve as biomarkers of oxidative stress (Dane and Şişman, 2021; Altwaijry et al., 2023). Pollutants may lead to histological changes in tissues and organs. Histological biomarkers lie at an intermediate level between the molecular and organ

levels and reflect the organism's integrated response to the negative effects. Gills, liver, and gonads accumulate toxicants at high concentrations, and histopathological evaluation of tissues from aquatic organisms has been considered an important indicator in environmental pollution monitoring (Şirin et al., 2024).

Gills are directly in contact with the toxicants present in the water. Therefore, gill alterations are good indicators of toxicant effects in many laboratory and field studies (Maharajan et al., 2016; Peyghan et al., 2021; Sangur et al., 2021; Moussa et al., 2022; Santos et al., 2023). The liver is a target organ; it is the primary organ for detoxifying xenobiotics, storing glycogen and releasing glucose into the blood, and synthesizing most blood components. Hepatic histopathological changes are a valuable tool for assessing the toxic impact on metabolic processes in fish (Andersen et al., 2015; Hussain et al., 2021; Gusso-Choueri et al., 2022; Erdoğan, 2023). The gonads are also important organs in toxicological studies. Toxicants accumulated in gonads may damage reproductive function and subsequent reproductive success (Feist et al., 2015; Dane and Şişman, 2021), thereby reducing the quality of future offspring (Bhat et al., 2023). Blood is the multifunctional system of an organism that transports endogenous and exogenous substances, including xenobiotics, to all tissues and organs. Blood and its serum components defend the organism from infections and toxic chemicals, and biochemical parameters of the blood, such as immune and antioxidant response, and abnormalities in the erythrocyte nucleus, are good biomarkers of the health status of the organism (Rezakhani et al., 2020; Altwaijry et al., 2023; Saoca et al., 2023; Sayed et al., 2023).

In this study, the black scorpionfish, *Scorpaena porcus* has been selected as the target species because it is a sedentary coastal fish that does not migrate and is available for study throughout the year; moreover, its biology and ecology have been well studied previously. It is a benthic species inhabiting bottom biotops (Rafrafi-Nouira et al., 2016; Yedier and

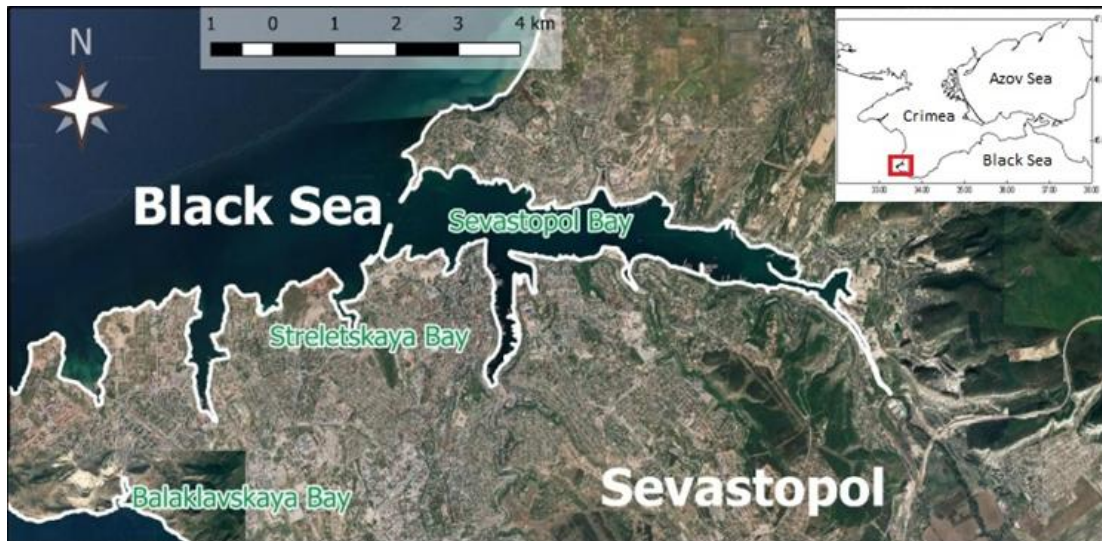

Figure 1. The map of the sampling bays.



Figure 2. Streletskaya Bay and Balaklavskaya Bay (Sevastopol, Black Sea).

Bostanci, 2021a, b). Additionally, the black scorpionfish was used as an indicator organism to evaluate the health of marine coastal ecosystems (Ferri et al., 2012; Çulha et al., 2016). Hence, this study aims to assess and compare the health status of black scorpionfish caught in two anthropogenically impacted bays in Sevastopol (Black Sea) using a series of histological and biochemical biomarkers. The main objective of this study was to determine, using various fish biochemical and histological biomarkers, which bay, characterized by similar levels of pollution, has worse living conditions for fish.

Materials and Methods

Sampling sites: Both tested bays in Sevastopol are located in the coastal area of the city (Fig. 1). Municipal effluents, maritime transport, the navy, atmospheric precipitation, recreation, and fisheries pollute them. Streletskaya Bay (Fig. 2) is the most

susceptible to human impacts. Its length is estimated at 2.13 km; the maximum width is 0.9 km; the depth at the bay entrance is 20 m, and at the deepest point it is 2 m (Kuftarkova et al., 2008). Intensive navigation, fishery, and recreation are observed here. Fuel docks and shipyards are located along its coasts; their drainage, along with discharges from municipal treatment plants and two stormwater sewer systems, significantly pollute the marine environment (Sergeeva et al., 2010).

Balaklavskaya Bay (Fig. 2) is located in the southern part of the city. It is a semi-closed basin with a width of 200 m and a depth of 30 m (Orekhova et al., 2018). The length of the coastline is 3.33 km, and the average depth is 12.5 m. Bathymetry and orography of the bay have significantly changed since the end of the 19th century and in the 20th century, especially in the northern shallow part, where it has increased from 1.83 m to 4-5 m, as a result of artificial deepening of



Figure 2. Black scorpionfish, *Scorpaena porcus*.

the bottom. A limited water exchange balance characterizes Balaklavskaya Bay. It is divided into the shallow part at the top of the basin, the central part, the southern deep bottom wide part, and two narrow parts. The main factors affecting the Balaklavskaya Bay are a specific hydrological regime and anthropogenic activity (Gurov et al., 2015). There are two polluted sites in it: one is the shallow part, which is contaminated by the anthropogenic sources, namely yachting, domestic sewage, and coastal infrastructure (Kotelyanets et al., 2019). The other is in the southern part of the bay, near the sewage pipe that drains approximately 3,000,000 m³/year of municipal sewage into the bay.

Water quality sampling and assessment: The water temperature at the fish-catchment site was measured directly in the sea using a HANNA Instruments Check Temp-1 electronic thermometer. Water samples were taken from the sea in 2-L plastic bottles and immediately transferred to the laboratory. The water salinity was determined with a PAL-06S LTA GO refractometer (Japan) and expressed in ppm (‰). The pH value, redox potential (Eh), and dissolved oxygen concentration were analyzed under laboratory conditions using an Expert-001 analyzer (Econix-Expert Moexa Ltd., Moscow, Russia) and corresponding selective electrodes from Volta (St. Petersburg, Russia). The optical density at 525 nm (OD₅₂₅) and the transparency of the water at the same wavelength were measured with the Expert-003 photometer (Econix-Expert Moexa Co Ltd., Russia).

Fish were collected in two bays using a fixed seine

with mesh size: 10.0, 12.5, 16.0, 22.0, 25.0, 30.0, 35.0, 38.0 and 45.0 mm (Fig. 3). Fish were caught in summer period (June, 23-25 and July, 2-7, 2020) in Streletskaya Bay (n = 23 specimens, 12 females and 11 males) and in Balaklavskaya Bay (n = 16 specimens, 11 females and 5 males). The fish were immediately placed in the aerated tank, transferred to the laboratory, and anesthetized with MS-222 (10 mg/L). The fish's ages ranged from 2+ to 6+. The age of the fish was determined by otoliths, for which they were broken, the broken parts were polished, and they were moistened in a glycerin-alcohol solution (3:1). Using a Micros MC 300 microscope, the images were viewed in transmitted light; the adjacent opaque and hyaline layers were taken as 1 year.

The total body length ranged from 104 to 224 mm, and body mass ranged from 19.4 to 260.6 g. The gonads maturation stage was III (in the large ovaries, due to vitellogenesis, oocytes are pigmented; the testes, which are elastic to the touch, increase in size; when cut at the beginning of the stage, the edges are sharp, and at the end they become swollen) and IV (in the ovaries, vitellogenic oocytes have reached sizes, mature eggs are easily separated from the stroma; in the large testes, a drop of sperm appears on the cut).

Histological processing: For histological analysis, the gills, liver, and gonads were fixed in a mixture of formalin, ethanol, and acetic acid (9:3:1). Gills, gonads, and liver were selected for histological analysis. Organs were fixed in Brodsky's mixture (9 parts of 40% neutral formalin, 3 parts of 95% ethyl alcohol, and 1 part of glacial acetic acid). Paraffin-embedded blocks have been prepared according to the standard procedure (Mikodina et al., 2009). Tissue sections were stained with Heidenhain iron hematoxylin and assessed using the AxioCam MRc5 video camera and the licensed AxioVision 4.7.1 software. The area of the outlined lesions was expressed as a percentage of the total area, and the mean was calculated from five randomly selected sections. The tissue thickness was 5 µm.

Biochemical assays: For biochemical determinations, blood was collected by caudal arterial puncture, and serum was separated. The red blood cells (RBC) were

processed as described by Rudneva (1997). The sediment, which contained RBCs, was washed three times with cold 0.85% NaCl solution, then lysed by adding 5 volumes of distilled water for 24 h at 4°C. The enzyme activity was determined in the lysates immediately after preparation.

Antioxidant enzyme activities in the supernatants were determined using standard methods. The enzyme activities of superoxide dismutase (SOD), catalase (CAT), peroxidase (PER), and glutathione reductase (GR) were determined spectrophotometrically in lysates immediately after preparation, using the methods described by Rudneva (1997).

Enzyme activities were expressed as units (U) per ml of RBC. Superoxide dismutase (SOD, EC 1.15.1.1) was assayed based on inhibition of the reduction of nitroblue tetrasolium (NBT) with NADH mediated by phenazine methosulfate (PMS) under basic conditions (Nishikimi et al., 1972). All measurements were performed in 0.017 M sodium pyrophosphate buffer (pH 8.3) at 25°C. The reaction mixtures contained 5 µM NBT, 78 µM NADH, 3.1 µM PMS, and a 0.1 ml sample; the final volume was 1.5 ml. The reaction was monitored at 560 nm using a spectrophotometric cuvette. Catalase (CAT, EC 1.11.1.6) was measured using the hydroperoxide-reduction method (Asatiani, 1969). Peroxidase (PER, EC 1.11.1.7) activity was measured spectrophotometrically using the benzidine reagent (Litvin, 1981). The reaction mixture contained 1 ml of acetate buffer (pH 5.4), 0.4 ml of 0.09% benzidine, 0.2 ml of 0.03% H₂O₂, and 0.2 ml of the sample. The reaction was monitored by spectrophotometry at 600 nm for 1 min at 20°C. Glutathione reductase (GR, EC 1.6.4.2) activity was assayed spectrophotometrically using a method modified after Goldberg and Sparner (1987). The reaction mixture contained 0.1 ml mM NADPH, 0.5 ml 7.5 mM oxidized glutathione, 0.2 ml mM EDTA, and 2 ml 0.05 M phosphate buffer, pH 8.0. After incubation for 10 min, the mixture's extinction was measured at 340 nm. The enzyme activities were expressed in units (U).

Total soluble protein concentration was quantified spectrophotometrically using the method of Lowry et

al. (1951). The SH-residues in fish blood serum were analyzed according to the method described by Folomeev (1981). The reaction mixtures contained 0.1 ml of blood serum, 1 ml of distilled water, 1 ml of 6 M KI, 3 drops of 5% starch solution, and 3.9 phosphate buffer, pH 7.6. The reaction was initiated by adding 0.3 mL of 0.001 N I₂ solution, and the extinction was measured at 500 nm. The concentration of SH-residues was calculated in µmol.

Statistical analysis: Biochemical determinations of fish blood, hydrochemical parameters were carried out using the Mann-Whitney test (Halafyan, 2008). All numerical data are given as means ± SD. To analyze the biochemical parameters of fish from two bays, one-way analysis of variance (ANOVA) with Tukey's post hoc test was conducted. The normality of distribution was assessed using the Shapiro-Wilk test. When determining sample normality and comparing samples, the standard significance level of $P=0.05$ was used. Statistical analysis of histological and biochemical data was performed using Statistica (StatSoft, Inc., version 6). The graphs were constructed using Microsoft Office Excel 2007 and Statistica v6.

Results

Hydrochemical parameters of the water in the Sevastopol bays: Table 1 shows the hydrochemical parameters of the Streletskaia and Balaklava bays. A comparative analysis of the hydrochemical characteristics of the two studied bays reveals several differences. The concentration of oxygen was similar, while the salinity in Balaklavskaya Bay was higher than in Streletskaia Bay. By contrast, Eh was higher in Streletskaia Bay. Transparency did not differ significantly, whereas OD₅₂₅ in Balaklavskaya Bay was approximately 3-fold higher.

Histopathological characteristics

Gonads' histopathology: In the adult black scorpionfish, gametes of various stages were found in the gonads. Adult females exhibited different ratios of normal, pathological, and vitellogenic oocytes and empty follicles following the previous spawning. In all specimens, atresia of vitellogenic oocytes of earlier

Table 1. Chemical and physical characteristics of the water in the Streletskaya and Balaklavskaya bays (given in parentheses of three to five determinations).

Parameters	Streletskaya Bay	Balaklavskaya Bay
Concentration O ₂ , mg/l	9.11±0.3	8.96±0.2
Salinity, ‰	12.1±0.1	17.8±0.1*
pH	7.01±0.2	7.33±0.1
Eh, mV	-27.5±0.5	-47.7±0.3*
Optical density, OD ₅₂₅	0.007±0.001	0.019±0.001*
Transparency, %	98.45±2.25	95.82±3.04
Temperature, °C	22.1±0.1	22.2±0.2

*Significant differences

Table 2. Ratio (%) of various generations in the testes of the black scorpionfish from the Sevastopol bays.

Bays	Streletskaya Bay		Balaklavskaya Bay	
	1+...2+	3+...4+	3+...4+	6+
Age (n, number of specimens)	4 sp.	6 sp.	4 sp.	1 sp.
Spermatogonium	32.8	37	45.75	51
% Spermatocytes	33	29.83	35.25	38
Spermatids	30.5	27.83	19	11
Sperm	3.8	7	0	0

Table 3. Ratio (%) of pathologies of gills in the black scorpionfish from the Sevastopol bays.

Pathologies	Streletskaya Bay	Balaklavskaya Bay
Confluence of lamellas	71	18
Hemostasis	96	50
Desquamation	75	36
Edema of epithelium	86	45
Degeneration of lamellas	82	31
Necrosis of epithelium	92	41

generations was observed. A comparative study of age-matched groups in the Streletskaya and Balaklavskaya bays revealed a common trend. In the 2+ age group, the level of atresia of vitellogenic oocytes was higher than in the 5+ and 6+ year-old groups (Figs. 4, 5, 6).

In the females from the Streletskaya Bay, all gametes in the gonads of young fish were previtellogenic oocytes. In the ovaries of the older age fish, there were oocytes of all generations and empty follicles after the previous spawning period. In all individuals, resorption of oocytes from the next generation was detected (Fig. 4a, b), and total atresia of vitellogenic oocytes was observed in one female (Fig. 4c, d). However, the pool of oogonia and oocytes of the early prophase of meiosis was found intact (Fig. 4e, f).

Thus, significant pathological changes were not observed in the testes of the black scorpionfish from both bays. However, there were differences in the

gamete ratios. In the young males from the Balaklava Bay, spermatogonia and spermatocytes dominated, and spermins were absent, while in the testes of fish from the Streletskaya Bay. This ratio was similar, but mature gametes were accompanied by a shorter reproductive cycle (Table 2, Fig. 6).

Gill histopathology: Histological analysis of the gills revealed different pathological changes, from rare, relatively normal tissues (Fig. 7a, b) to those with significant damage (Fig. 7c, d). Changes of the gills, namely hemostasis, desquamation, edema of respiratory epithelium, degeneration of lamellae, and necrosis of epithelium, were found in more than 50% of the fish. In some individuals, several types of damage were determined. The majority were found in fish from Streletskaya Bay (Table 3). Desquamation (detachment of epithelium) was also found, and more than 50% fish showed signs of degeneration and necrosis of the respiratory lamellae. In several individuals, significant tissue anomalies may have

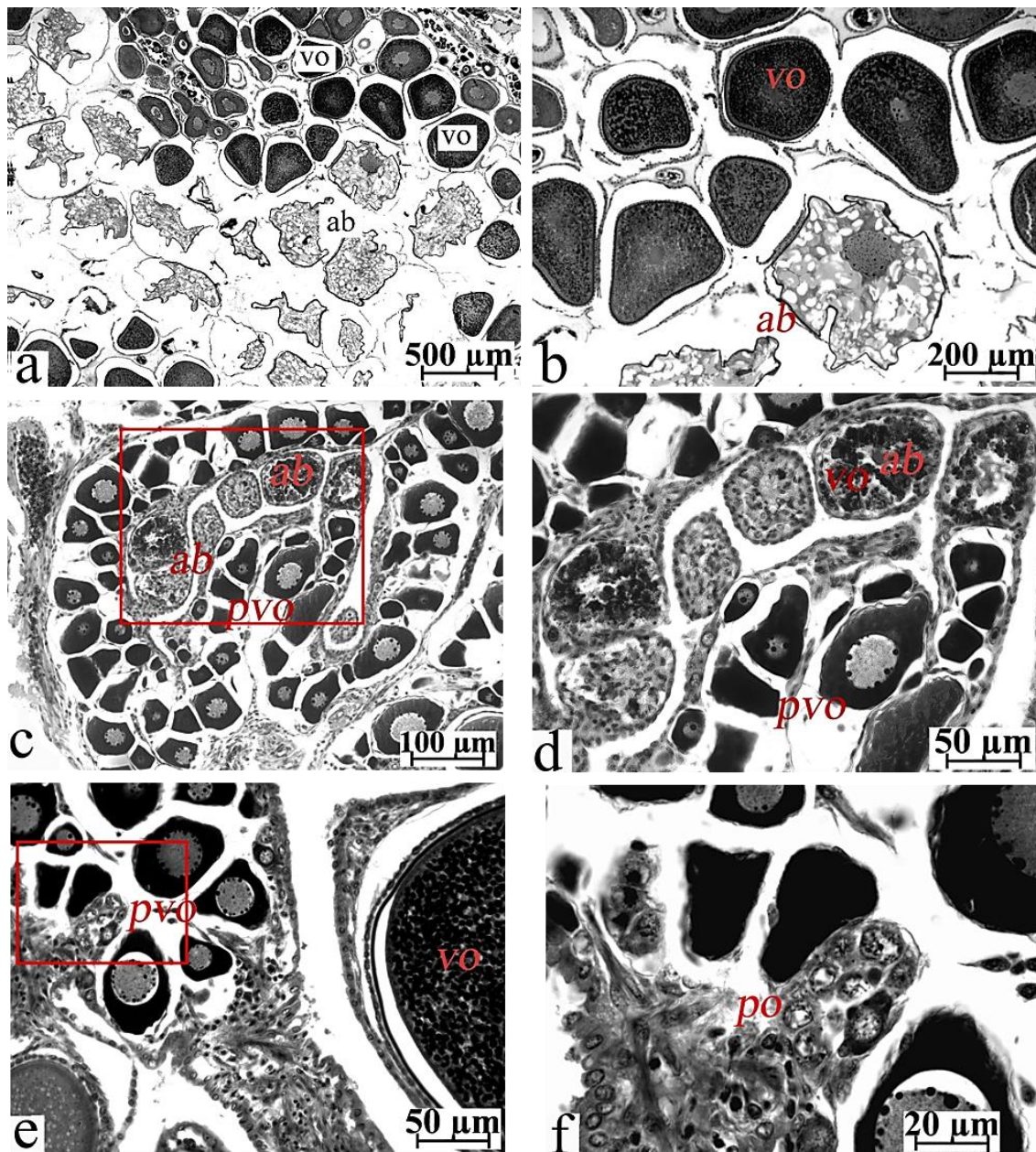


Figure 4. Ovaries of the black scorpionfish caught in the Streletskaia Bay. (a) an ovary at the III stage of maturation; atresia of vitellogenic oocytes of the elder generation, (b) the same at a larger magnification (the red rectangle), atresia of the oocyte in the period of maturation, (c) complete degeneration of vitellogenic oocytes; only previtellogenic oocytes are present in the ovary, (d) the same at a larger magnification (the red rectangle); the presence of atretic bodies and non-damaged previtellogenic oocytes, (e) accumulation of gametes of the reserve stock is present among previtellogenic oocytes and degenerative empty follicle shells, and (f) the same at a larger magnification (the red rectangle); accumulation of gametes at the stages of pachitena and zigotena. The iron hematoxylin by Heidenhain (Symbols: ab – atretic body, pvo – previtellogenic oocyte, vo – vitellogenic oocytes, and po – nest of pachitene stage oocytes).

contributed to impaired gill function.

Unlike the fish from the Streletskaia Bay, the number of pathological gills in the black scorpionfish from the Balaklavskaya Bay was much lower (Fig. 7e, f). The most frequent pathology, which was found in 50% of the fish, was disturbed blood circulation in lamellae, accompanied by hemostasis and edema of

the respiratory epithelium (Fig. 7g). Degeneration of lamellae and necrosis of epithelium were also found (Table 3). In several individuals, the neoplasma of the cartilage of the gill leaf (chondroma) was identified (Fig. 7h). Hence, the majority of fish from both bays exhibited numerous pathological changes in the gills, filaments, and respiratory epithelium, including

neoplastic transformations such as chondroma. The number of pathologies was greater in the fish from

Streletskaya Bay compared to those from the Balaklavskaya Bay.

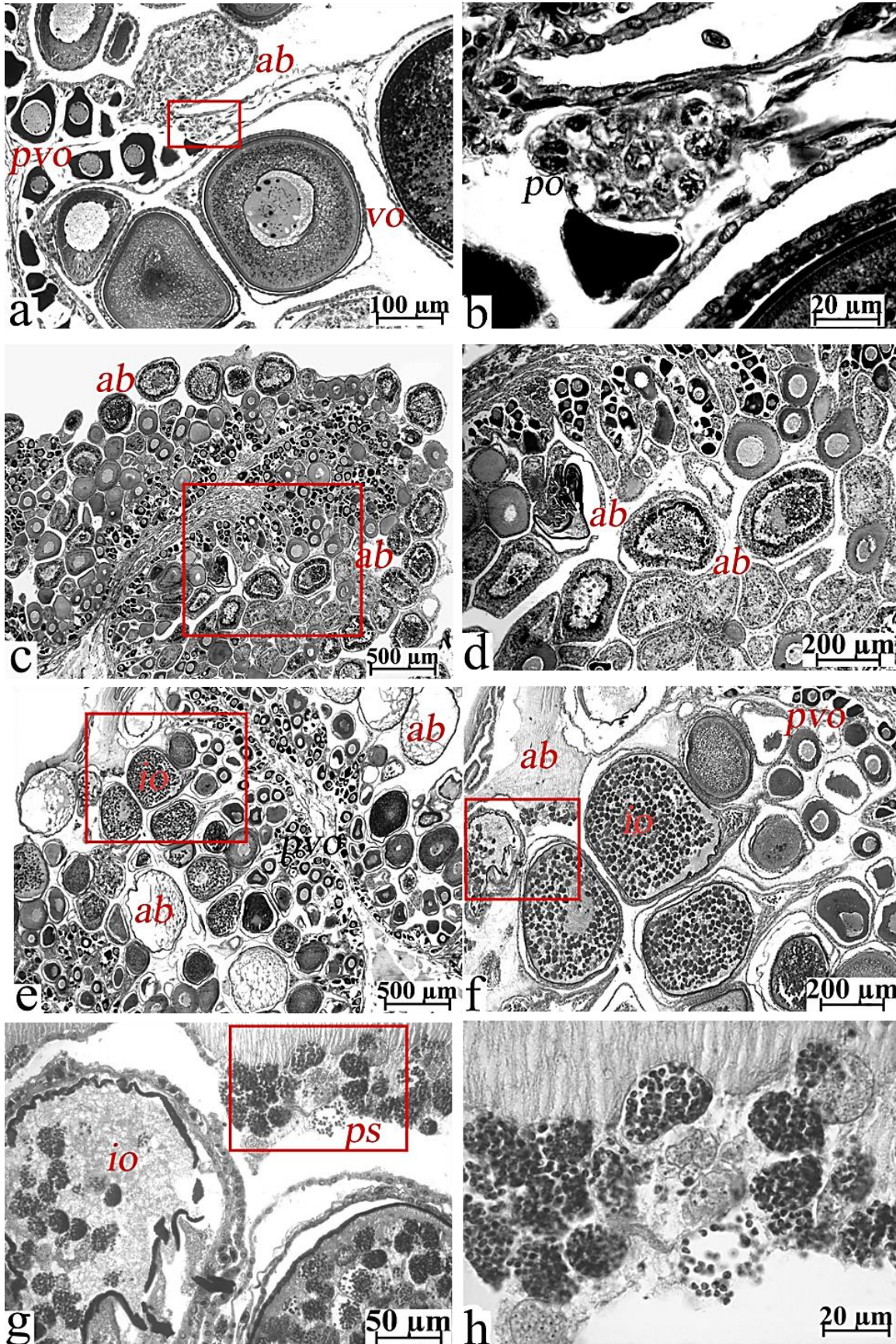


Figure 5. Ovaries of the black scorpionfish from the Balaklavskaya Bay. (a) accumulation of early meiocytes between oocytes of different generations and atretic bodies in an ovary at the III stage of maturation, (b) the same at a larger magnification (the red rectangle); accumulation of oocytes of the early prophase of meiosis (pachitena), (c) atresia of all gametes at the period of vitellogenesis in an ovary at the III stage of maturation, (d) the same at a larger magnification (the red rectangle); total resorption of all vitellogenic oocytes and ovules among degenerative empty follicle shells, (e) an ovary at the III stage of maturation; vitellogenic oocytes infected by parasitic microorganisms, (f, and g) the same at a larger magnification (the red rectangle); oocytes with damaged shells, and (h) cysts of parasites in ooplasm enter the interoocyte cavity; parasite spores leave the cysts. The iron hematoxylin by Heidenhain (is – infected oocyte, and ps – parasite spores).

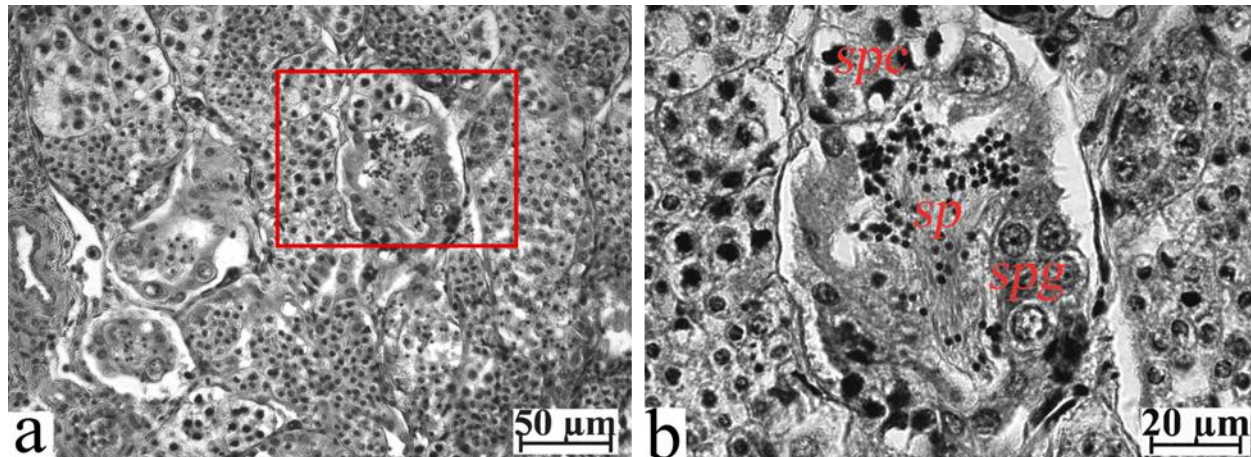


Figure 6. Testes of the black scorpionfish from the Streletskaia Bay. (a) testis at the III stage of maturation; cysts are full of the gametes of various generations, (b) the same at a large magnification (the red rectangle); spermatocytes and spermatids. The iron hematoxylin by Heidenhain (Symbols: spg - spermatogonium, spc - spermatocytes, sp – spermatids).

Liver histopathology: For histological assessment of the liver, the hepatocytes were classified into three morphofunctional groups: normal, lipid dystrophy, and intermediate. Hepatocytes of the first group were large, had a clearly visible nucleus with a single nucleolus, and basophilic cytoplasm. In fish with lipid dystrophy, hepatocyte nuclei were pushed back by large lipid droplets to the periphery of the cell. The intermediate state of the hepatocyte was characterized by basophilic cytoplasm and lipid droplets.

In 50% of fish from the Streletskaia Bay, the hepatocytes were characterized by a high content of lipid inclusions (Fig. 8a), and it was higher in females compared to males (Table 4). Most fish had no lipid dystrophy; however, several females showed degeneration of the hepatic parenchyma with cell debris in the cavities and erythrocytes (Fig. 8b). On the contrary, in most females and in all studied males from the Balaklavskaya Bay, the lipid dystrophy was identified (Table 4). The cytoplasm of the larger hepatocytes was full of lipid droplets, and the single nuclei were pushed to the cell periphery (Fig. 8c, d). Thus, certain anomalies, including degeneration of the

hepatic tissue and lipid dystrophy of the hepatocytes, were found in the livers of several specimens of fish from the Streletskaia Bay and almost in all examined fish from the Balaklavskaya Bay. These changes were more common among males of the Balaklavskaya Bay.

Blood biomarkers: In the Streletskaia Bay, activity of SOD and PER was much higher ($P < 0.05$), while the activity of the other two enzymes (CAT and GR) was nearly the identical (Fig. 9). The ratios of the enzyme activities (CAT: SOD: PER: GR) in fish blood differed: in the Balaklavskaya Bay it was estimated at 1: 84.2: 73: 1.2 and in the Streletskaia Bay as 1: 176: 211.6: 2.4. No significant differences were found in the concentration of the total protein and SH residues, while the content of non-protein ones was significantly higher ($P < 0.05$) in the fish in Balaklavskaya Bay (Fig. 10). The ratio of non-protein/protein SH residues in the serum of the fish of the Balaklavskaya Bay was 1.6, while in the fish in the Streletskaia Bay it was 1.1. The results demonstrated differences in antioxidant parameters between the RBCs and serum of black scorpionfish at the two study

Table 4. Ratio (%) of the black scorpion fish from the Sevastopol bays with pathologies of the liver.

Bays	Streletskaya Bay		Balaklavskaya Bay	
	Female	Male	Female	Male
Sex				
Lipid dystrophy	46	40	72	100
Intermediate state	15	40	27	0
Normal	38	20	0	0

locations.

Discussions

The present study enabled evaluation of the health of the model species, black scorpionfish, in two Sevastopol bays and comparison of living conditions across the studied sites. The coastal waters of Sevastopol city are highly impacted by anthropogenic activity. The bays are contaminated by municipal effluents, maritime transport, naval activities, atmospheric precipitation, and recreational activities. Streletskaya Bay is characterized by a high level of anthropogenic impact, namely intensive shipping, fuel docks, and shipyards along its coast. Effluents from two municipal wastewater treatment plants and two storm drainage systems pollute the marine environment (Ovsyany et al., 2001; Sergeeva et al., 2010). Since the beginning of 2000, water and sediments in Streletskaya Bay have contained significant levels of oil, heavy metals, chlorinated hydrocarbons, nutrients, and suspended organic matter (Mironov et al., 2003). The level of petroleum hydrocarbons in bottom sediments was estimated as 705 mg/100 g wet weight (Eremeev et al., 2008). The average concentrations of chlorinated and petroleum hydrocarbons in bottom sediments were estimated at 1.33 and 715.5 mg/100 g wet weight, respectively (Osadchaya, 2013). The concentration of these chemicals increased progressively during 2003-2009 by 1.2-1.5 times compared to the 1990s. The concentrations of six indicator PCB congeners (Σ PCB6) and Σ DDT in the bottom sediments of this reservoir were estimated as 121 and 51 ng/g, respectively (Malakhova, 2009). The mercury level exceeded the permissible limit by 5-10 times, ranging from 460 to 1063 ng/g dry weight (Kostova and Plotitsina, 2011). During 2009-2015, the highest content of chloroform-extractable substances in bottom sediments was observed in Streletskaya Bay.

Their values ranged from 975-1493 mg/100 g dry weight, which corresponds to IV-V pollution levels. The average concentration of petroleum hydrocarbons in bottom sediments ranged from 560 mg/100 g to 360 mg/100 g of dry weight, which significantly exceeded standard levels (Solovieva et al., 2018). However, over the last decade, the navy's influence on the bay has decreased due to intensive construction of tourist and hotel complexes and shipyards along its coast (Tikhonova et al., 2018). Despite this, long-term anthropogenic pollution has affected the marine ecosystem and its biota.

Anthropogenic activity and water dynamics are the main factors influencing the ecological state of Balaklavskaya Bay (Kuftarkova et al., 2008; Lomakin and Popov, 2011). The most heavily polluted areas in the bay are the shallow northern areas, into which the Balaklavka River flows; anthropogenic pollution from the coast, together with low-water changes, has led to the accumulation of organic matter in this area. Another highly contaminated site is located in the southern part of the bay, adjacent to a wastewater treatment plant that processes ~3,300,000 m³/year of industrial wastewater (1,100,000 m³/year), energy sources, precipitation, and municipal effluents (Popov et al., 2005; Gurov et al., 2015). In the water and bottom sediments of Balaklavskaya Bay, the content of trace elements and metals, chloroform-extractable substances, and petroleum hydrocarbons depends on natural geochemical processes and anthropogenic sources of pollution. A relationship has been established between the content of chloroform-extractable substances and petroleum hydrocarbons. The content of clayey material in the water of Balaklavskaya Bay ranged from 58.2 to 65.9%; the highest values were observed in the western and northwestern parts of the reservoir. The concentration of chloroform-extractable substances in the bottom sediments of Balaklava Bay varies widely, and the

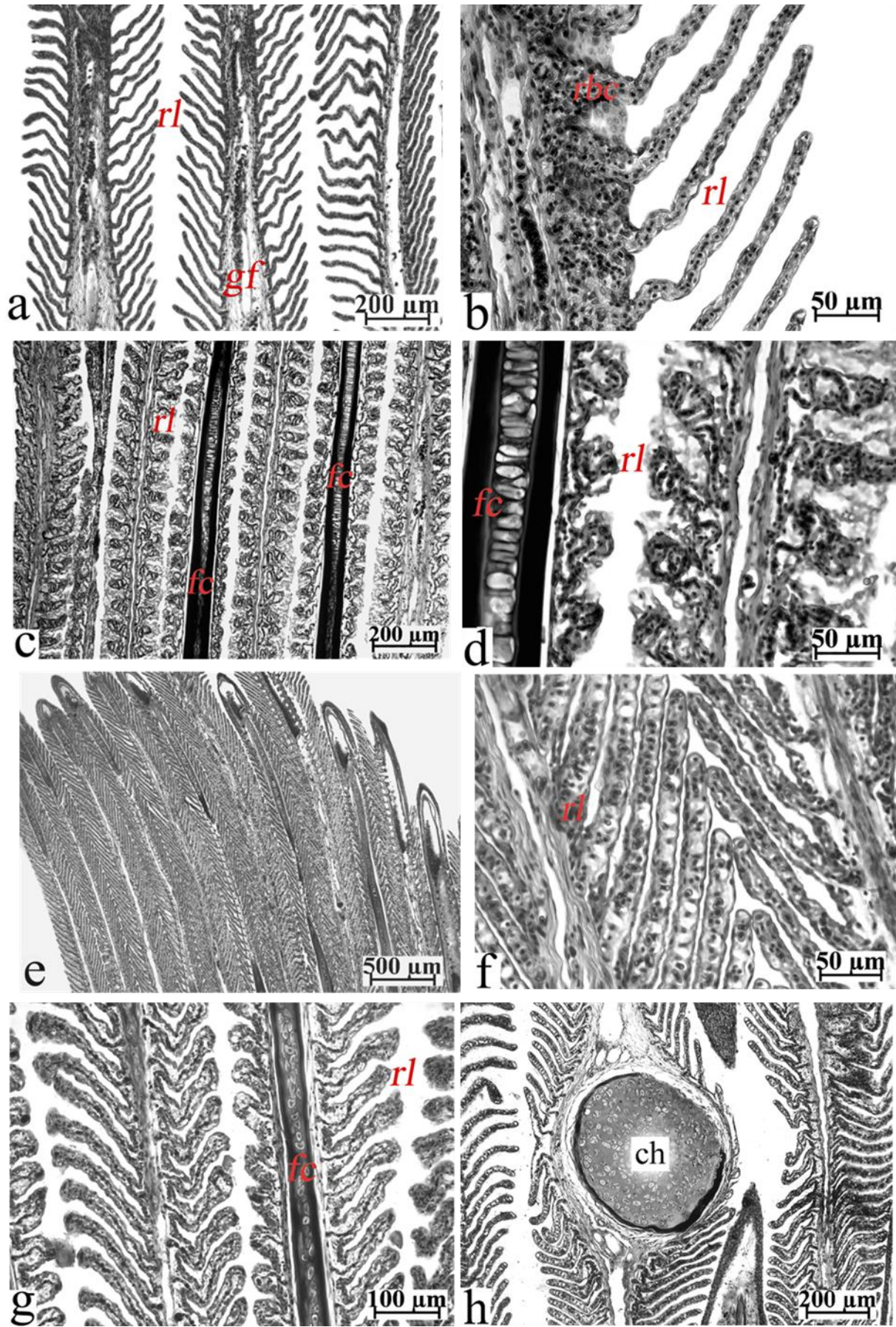


Figure 7. Pathological changes in the gills of the black scorpionfish from Streletskaya Bay (a-d) and Balaklavskaya Bay (e-h). (a) thicker filaments of the gills, (b) the same at a larger magnification; respiratory lamellas without any changes, (c) gills epithelium with significant damage, (d) the same at a larger magnification multiple pathologies such as confluence of lamellas, hyperemia, desquamation with degeneration of the respiratory lamellas, (e) normal gills; (f) the same at a larger magnification; respiratory epithelium without any pathological changes, (g) gills with anomalies including edema and desquamation of the respiratory epithelium, and (h) chondroma of the gill's filament. The iron hematoxylin by Heidenhain (rl – respiratory lamellae, gf – gill filaments, rbc – red blood cells, fc – filament cartilage, and ch – chondroma of the filament cartilaginous).

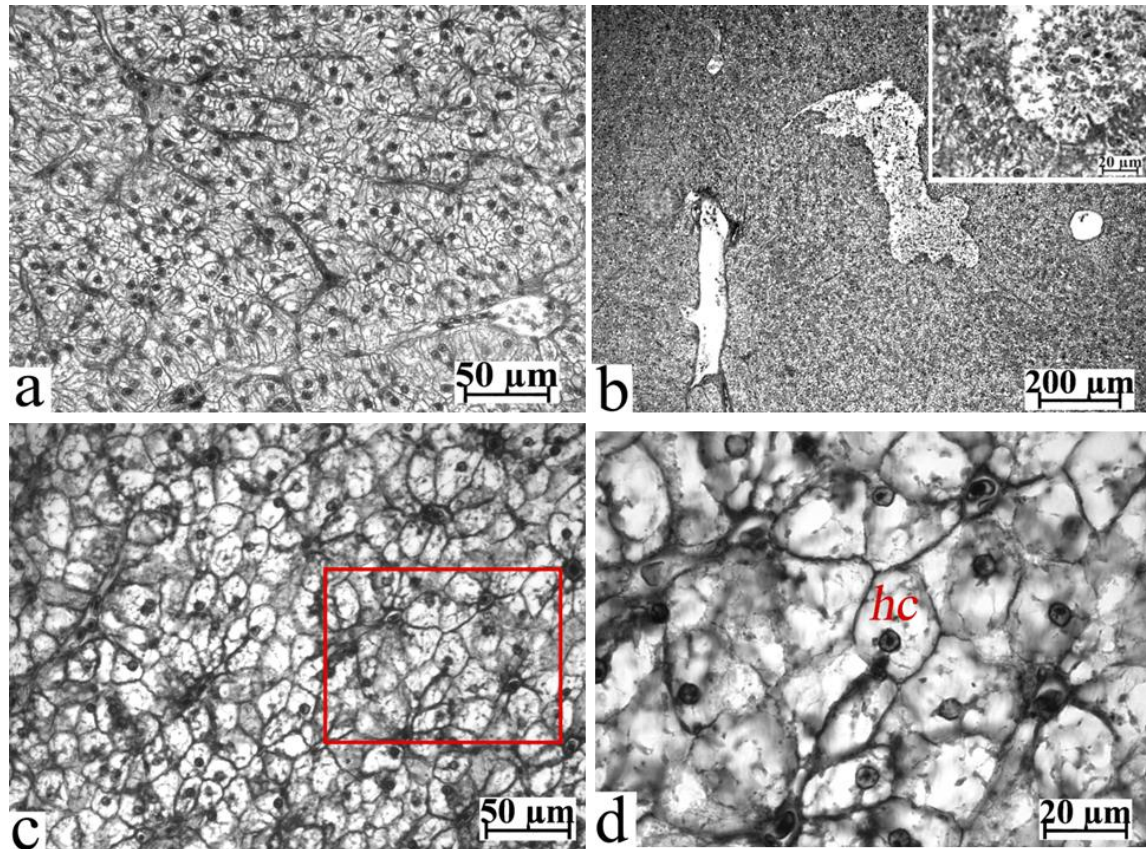


Figure 8. Histopathological changes in the livers of the black scorpionfish from the Streletskaya Bay (a, b) and Balaklavskaya Bay (c, d). (a) lipid dystrophy in the hepatocytes, (b) degeneration of the hepatic tissue with cell debris in the cavern (highlighting site), (c) hepatic section with hyperemic hepatocytes, and (d) the same at a larger magnification (the red rectangle); hepatocytes are full of lipids. The iron hematoxylin by Heidenhain. (hc – hepatocyte).

average concentration of heavy metals (Cd, Cu, Ni, Pb, Ag, Zn) is estimated at 521 mg/kg in bottom sediments. Increased concentrations of heavy metals (Pb, Cr, Zn, Cu, and Sr) were observed in the northeastern and central parts of the water area, whereas concentrations were lower in the northwestern and eastern parts. The carbohydrate content of petroleum in 2005 ranged from 44 to 582 mg/100 g dry weight and was comparable to that in 1992 (21-562 mg/100 g dry weight) (Orekhova et al., 2018; Kotlyanets et al., 2019). During 2005-2015, a general trend toward a decrease in the content of organic matter in the bay's bottom sediments was observed; this is interpreted as a result of changes in

anthropogenic loading. The average content of organic carbon in the bottom sediments of Balaklavskaya Bay was two to three times lower than in other bays of the Sevastopol region that experience constant anthropogenic pressure. However, pollution of Balaklavskaya Bay with untreated urban, storm, and industrial wastewater results in the formation of local bottom zones in which sediments are oversaturated with organic matter ($Torg > 2.5\%$). This pollution negatively affects the ecological state of the marine environment. In the seawater of Balaklavskaya Bay, the concentration of petroleum hydrocarbons exceeded the permissible norm by 10-100 times. With the legal level (Mezentseva et al., 2005). Thus, the

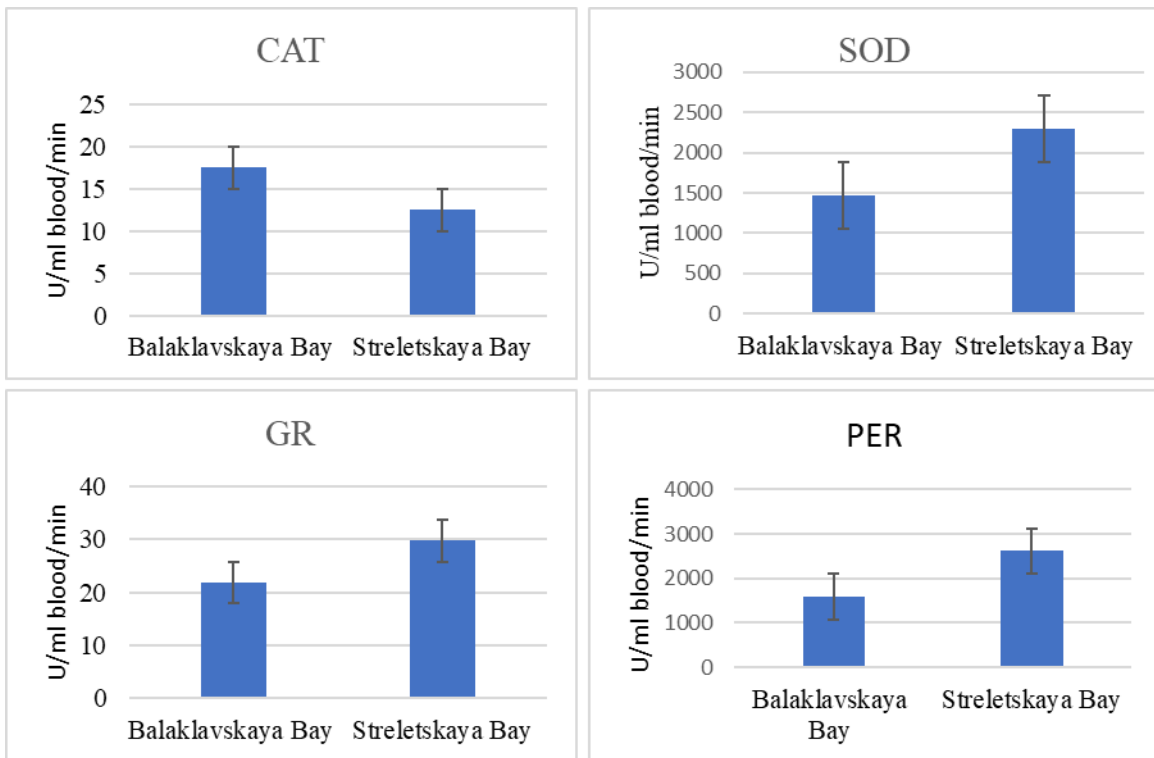


Figure 9. Antioxidant enzyme activities in RBC of the black scorpionfish from two Sevastopol bays (Mean \pm SEM). CAT = Catalase, SOD = superoxide dismutase, PER = peroxidase, and GR = glutathione reductase.

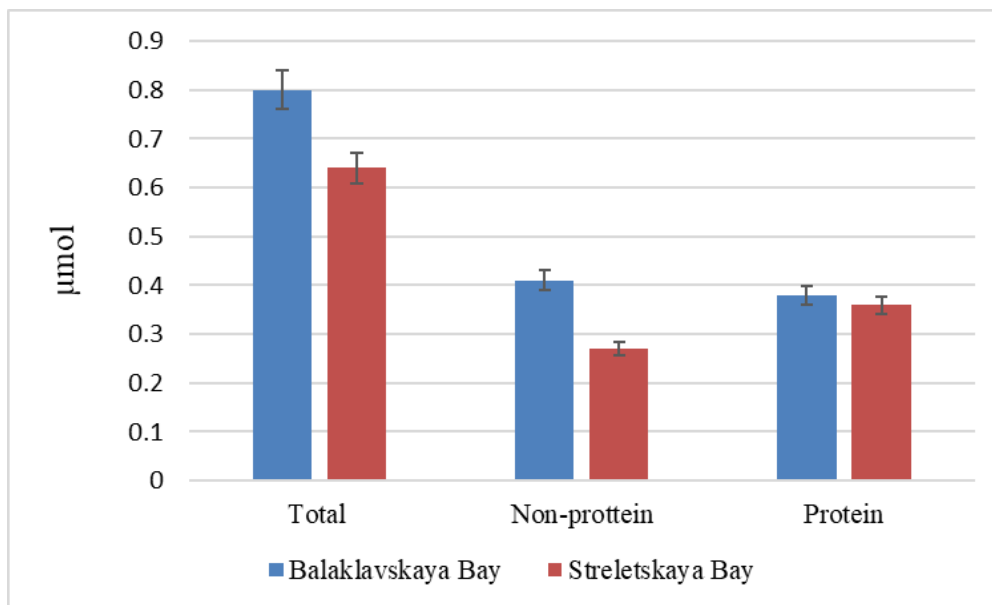


Figure 10. Concentration of the SH residues in the blood serum of the black scorpionfish from two Sevastopol bays (μmol , Mean \pm SEM).

tested bays are characterized by high anthropogenic loading, as many pollution sources are located along their coasts.

In our study, the hydrochemical characteristics of the two bays differed, attributable to differences in their hydrological regimes and anthropogenic load.

Salinity was higher in Balaklavskaya Bay than in Streletskaia Bay, possibly due to differences in wastewater inflows to the bays. Significant differences in Eh values also indicate differences in redox processes between the two bays, as confirmed by other researchers (Solov'eva et al., 2018; Lomakin

and Popov, 2011). Optical density (OD₅₂₅) was also 3 times higher in Balaklavskaya Bay, which indicates a significant excess of suspended and dissolved substances in this site. These differences may result from both complex anthropogenic impacts on the bays and the specific influence of hydrological features. Therefore, it is difficult to determine the extent of pollution in marine ecosystems and biota. In this case, the black scorpionfish was selected as an indicator, and histological analysis of the gonads, gills, and liver revealed several differences in the tissues of fish from the two locations.

Gonadal state is the primary indicator of reproductive health in species and populations (Gashkina et al., 2022; Bhat et al., 2023). In our study, atresia of vitellogenic oocytes was observed in all examined females from both studied Sevastopol bays. This may be due to abnormalities in the processes regulating potential fertility (Brown-Peterson et al., 2011), as a major portion of the vitellogenic oocytes was resorbed. Streletskaya and Balaklavskaya bays showed a common pattern: in fish aged 2+, the level of atresia in vitellogenic oocytes was higher than in the 5+-6+-year-old groups, which may be explained by increased organismal stability in response to various unfavorable factors.

Our results are consistent with data obtained for various fish taxa, including coregonids, salmonids, cyprinids, groupers, and graylings, from different geographical zones (Selyukov, 2012; Shuman et al., 2019; Nekrasov et al., 2021). The main reason for these pathologies is the long-term deterioration of conditions at the onset of vitellogenesis (Corriero et al., 2021). However, previtellogenic oocytes and reserve germ cells in the fish ovaries were more resistant to potential toxic effects and developed normally. One can assume that potential endocrine-disrupting chemicals (EDCs) in municipal sewage in both bays can inhibit the transition from previtellogenesis to vitellogenesis, cause synthesis of 17 β -estradiol in follicle cells of the oocytes, and then inhibit synthesis of vitellogenin in the liver, resulting in the atresia of follicles (King Heiden et al., 2008).

Additionally, changes in the fish immune system in

the bays were linked to endocrine changes, supporting the finding of parasite-infected ovaries in 2 of 10 individuals in Balaklavskaya Bay. These parasites belong to *Microsporidia* (Summerfelt and Goodwin, 2006). Parasites located in the generative tissue destroy the mature gonads. In the ovaries, parasites inhibit the host immune response while they are situated within oocytes. The pathological effects of these parasites can be significant, on occasion leading to parasitic castration (Sitja-Bobadilla, 2009). In addition, parasites are good bioindicators of fish health at both polluted and non-polluted sites. The mean abundance and prevalence of parasites were higher in sculpin *Myoxocephalus scorpius* captured at a contaminated site than in those from the reference location (Khan, 2011).

The normal process of gametogenesis in the male black scorpionfish from both bays indicates the absence of critical pollution affecting the developing reproductive system. Generally, in males, compared with the female reproductive system, there are fewer "risk zones" that can disrupt the reproductive process. Thus, in our study, we did not observe significant gonadal changes in black scorpionfish from the tested bays, indicating that toxic chemicals were not present at harmful concentrations in the environment. However, changes in female gonads, particularly in younger age classes, can result from internal and external factors, including sex, age, spawning period, and water quality. In general, changes in the gonads were found more frequently in females than in males. These negative anomalies were observed in female gonads and may result from chronic pollution of marine environments, potentially affecting reproductive success by reducing gamete quality and posing a significant risk to the survival of fish populations (Feist et al., 2015).

Histological examination of the black scorpionfish gills showed several respiratory disturbances, such as hyperplasia of respiratory lamellae, which decreased the lamellar length and their availability for gas exchange significantly. Epithelial filament proliferation may reflect a chronic stress response that protects against toxicants, reactive oxygen species,

and parasites (Monteiro et al., 2008). In most black scorpionfish individuals from both studied bays, we found hemostasis of the gill epithelium, which was accompanied by the disturbance of column cells and damage to the integrity of the vessels with the excretion of large volumes of blood, which induced swelling of the lamellas and appearance of an aneurysm (Ahmed et al., 2013). The same abnormalities of the gill epithelium, an increase in the number and diversity of them with age, have been documented previously (Selyukov, 2012; Shuman et al., 2019; Nekrasov et al., 2021).

In the black scorpionfish from Balaklavskaya Bay, neoplastic transformation of the cartilage basis of the gill filaments (chondroma) was found, which was probably a result of infection and/or chronic inflammation. Chondromas in the basis of the gill filaments we observed previously in the mottled spinefoot *Siganus fuscescens* from the polluted coastal waters near the island Malapaskua (Philippines) (Selyukov et al., 2022). Under conditions of long-term pollution, a key functional feature of the gill epithelium is increased mucus secretion, as mucus cells protect the epithelium against xenobiotics. Additionally, histopathological effects of water contamination on fish gills can be accompanied by seasonal fluctuations in anthropogenic impact, particularly in recreational areas (Hussain et al., 2021).

Therefore, most of our findings on histopathological alterations in fish gills were comparable to those reported in the aforementioned studies. In general, the gills exhibited two types of responses to unfavorable environmental conditions: protective, characterized by inflammation, and compensatory, characterized by increased cell proliferation and mucus secretion (Cerqueira and Fernandes, 2022). However, the authors note that this division is relative, as proliferative growth in lamellar and filament epithelium provides both structural support and protective functions, while mucus secretion is also modulated by inflammatory mechanisms.

The liver is a multifunctional organ that plays a key

role in metabolic processes, the biosynthesis of vital molecules, biotransformation, detoxification, and the elimination of endogenous and exogenous waste substances. Lipid dystrophy of hepatocytes was observed in the liver of the black scorpionfish from both bays. In several females, degeneration of the hepatic parenchyma, with cellular debris and erythrocytes in the caverns, was also observed. These findings revealed that the fish's living conditions at both sites were unfavorable and that toxicants in the water and sediments induced hepatic cell alterations. Therefore, in the black scorpionfish from the Sevastopol bays, only small pathological changes were found, apart from medium and partly high levels of hepatocyte dystrophy and sometimes degeneration of the liver tissue, which can demonstrate the absence of highly toxic chemicals in the water of the tested bays. However, in our previous study, we found an increase in the number of MMC in the hepatocytes of *S. porcus* from Streletskaya Bay as compared with the fish from the less polluted Karantinnaya Bay, which is also located in the region of Sevastopol (Rudneva et al., 2017). Our findings agree with the results of other researchers, who demonstrated various histological pathologies, such as microvesicular lipid vacuolation, lipid accumulation, blood vessel congestion, nuclear and cellular degeneration, megalocytosis, karyomegally, bile stagnation, cholangitis, bile duct proliferation, lymphocytic infiltration, and spongiosis hepatitis were found in the liver of fish from polluted sites or at the experimental conditions (Agamy, 2012a,b; Andersen et al., 2015; Maharajan et al., 2016; Sangur et al., 2021; Moussa et al., 2022). The researchers also noted that seasonal fluctuations in anthropogenic load on water areas can lead to histological changes in the liver (Santos et al., 2022).

Histological alterations in fish gonads, gills, and liver tissues can indicate direct injurious effects of pollutants, which are in continuous contact with these tissues during ion exchanges, xenobiotic accumulation, biotransformation, and detoxification in the organs. During these processes, oxidative stress is induced, and increased ROS levels stimulate a variety of cellular and histological changes in fish.

Toxicity is associated with increased ROS generation, resulting in an imbalance between oxidative and pro-oxidative processes in the organism, pathological changes, disease, and, ultimately, death (Bhat, 2023; Altwaijry et al., 2023). Special enzymes protect organisms against ROS. In our study, we used blood cell biomarkers superoxide dismutase (SOD), catalase (CAT), peroxidase (PER), and glutathione reductase (GR). SOD protects organisms against oxidative damage by catalyzing the reaction of dismutation of superoxide anion to H_2O_2 , which is removed by CAT to H_2O . PER reduces both hydrogen peroxide and hydroperoxides also. GR maintains the homeostasis of the GSH/GSSG ratio under oxidative stress. Blood is a multifunctional system that unites all organs of the body. Changes in blood, particularly in antioxidants, accurately reflect alterations in the organism under the influence of adverse factors and thus can serve as reliable indicators of its status.

The activity of SOD and PER was higher in the erythrocytes of fish from the Streletskaya Bay, which was attributed to the induction of oxidative stress in the fish. The induction of SOD indicates a high generation of ROS in the RBC of fish from Streletskaya Bay. Thus, we can assume that the living conditions for fish from the Balaklavskaya Bay were more suitable than those in Streletskaya Bay. Our findings are in agreement with the histological characteristics of the target organs, which also demonstrated the worst health of fish from Streletskaya Bay compared to Balaklavskay Bay. Other researchers have also documented an elevation in SOD activity in the tissues of the African catfish, *Clarias gariepinus*, from a river ecosystem polluted with heavy metals (Turan et al., 2022) and from contaminated marine habitats (Kumar et al., 2021). The increase in CAT, SOD, GPX, and TBA reactive-substance levels in the livers and gills of *Oreochromis niloticus* and *C. gariepinus* collected from polluted sites, compared with animals from reference areas, was reported (Moussa et al., 2022). Similar results were observed in the gills, liver, and gut of the fish *Labeo rohita* inhabiting an Indian river polluted with heavy metals (Altwaijry et al., 2023). Additionally,

the authors of this study observed changes in RBC morphology attributable to heavy metal pollution, underscoring the importance of blood in oxidative stress analysis. Apoptosis and DNA damage in erythrocytes, together with an imbalance of the antioxidant profile, were observed in the adult tilapia exposed to volatile organic compounds (Sayed et al., 2023). The imbalance between ROS levels and antioxidant defenses induces oxidative stress, resulting in cellular dysfunction via peroxidation of lipids and proteins, damage to cell membranes and DNA, and the development of various pathologies, including histological changes. (Erdoğan, 2023; Salaro et al., 2023). Since the blood cells directly contact the gills and transport pollutants to the liver and other organs and tissues, they are used to assess oxidative stress and the fish's ability to scavenge excessive ROS (Agamy, 2012a, b).

In our study, CAT activity was similar in the RBCs of fish from both tested bays, whereas we demonstrated synchronous elevations in CAT and SOD activities. At the same time, the PER activity was much higher ($P < 0.05$) in the RBC of fish from Streletskaya Bay. Given that PER is an important enzyme for detoxifying H_2O_2 and organic peroxides (Temiz and Kargin, 2022), we can assume that PER also participates in the degradation of H_2O_2 as well as in the degradation of organic peroxides, and that its level correlates with an increase in SOD activity.

Continuous and chronic exposure to a mixture of different pollutants, especially heavy metals, increases the conjugation rate between them, low molecular weight components such as metallothioneins (MTs), tripeptide glutathione GSH and proteins, containing free SH residues (such as serum albumin) (Javed et al., 2017). The strong affinity of the SH residues in GSH and several serum proteins for metals explains the increase in GR activity in RBCs and the reduced content of non-protein SH residues in the serum of fish collected in Streletskaya Bay (abundant thiol molecules). It can be assumed that differences in the content of non-protein protein groups are associated with varying levels of metallothioneins, the synthesis of which increases in response to heavy metal

pollution (Ruttikay-Nedecky et al., 2013). We consider that the level of low-molecular-weight MTs in the blood serum of fish from Streletskaya Bay has increased as a response to high pollution in the water, because free SH residues could also scavenge ROS and play a protective role against oxidative stress and tissue damage in fish blood serum.

Conclusions

Our study has shown that, although pollution-level analyses did not reveal marked differences between the two tested bays, histopathological and biochemical biomarkers indicated that the examined fish are living under stressful environmental conditions. The health status of the model species, black scorpionfish, differed, indicating differences in the quality of the aquatic environment and in the living conditions for the biota. Various histopathological abnormalities were observed in the gonads, gills, and liver of black scorpionfish inhabiting two bays. Differences and severity of pathological alterations in fish from the tested locations may be related to pollutant types, concentrations, and interactions with water and sediment components. However, severe histological abnormalities were observed in the tissues of the black scorpionfish collected from Streletskaya Bay compared with the fish from Balaklavskaya Bay. In the red blood cells of the fish, collected from Streletskaya Bay, the antioxidant enzyme activities of SOD and PER in RBC were higher, while the concentration of total and non-protein SH residues in blood serum was lower than in individuals from Balaklavskaya Bay. Based on the level of antioxidant induction and the frequency of histopathological modifications, the black scorpionfish from Streletskaya Bay demonstrated greater stress and certainly more serious damage than the fish from Balaklavskaya Bay. As we see, when chemical approaches cannot be applied in marine environments, the use of proper fish biomarkers is a suitable tool for monitoring environmental stress and ecosystem health. They provide an adequate evaluation of the toxicological effects of long-term pollution on fish and can support further monitoring of bays

experiencing complex anthropogenic impacts.

Acknowledgments

We are particularly grateful to Dr. T. Bagnukova and L. Verzhenskaya for assistance with English editing. All authors have read and agreed to the published version of the manuscript. We are grateful to V. Chernov and L. Shuman for their assistance with sample collection and laboratory procedures. We thank Mr. O.V. Shaida for the photographs of Sevastopol bays.

Ethical Approval: All applicable international, national, and institutional guidelines for the care and use of animals have been followed. This work does not report the results of any studies involving human participants as research subjects.

Credit authorship contribution statement Irina Ivanovna Rudneva carried out biochemical determinations, wrote the manuscript, and approved the final version of it. Alexandr Germanovich Selyukov analysed the biometric and histopathological data, wrote the manuscript, and approved the final version. Innokenty Sergeevich Nekrasov analysed the histopathological data and statistical analysis. Valentine Grigor'evich Shaida provided hydrochemical determinations.

Funding: The research was partially financially supported by the Tyumen Oblast Government, as part of the West-Siberian Interregional Science and Education Center's project No. 89-DON (2).

References

- Agamy E. (2012a). Histopathological changes in the livers of rabbit fish (*Siganus canaliculatus*) following exposure to crude oil and dispersed oil. *Toxicologic Pathology*, 40: 1128-1140.
- Agamy E. (2012b). Histopathological liver alterations in juvenile rabbit fish (*Siganus canaliculatus*) exposed to Arabian light crude oil, dispersed oil and dispersant. *Ecotoxicology and Environmental Safety*, 75: 171-79.
- Ahmed M.K., Al-Mamun M.H., Parvin E., Akter M.S., Khan M.S. (2013). Arsenic induced toxicity and histopathological changes in gill and liver tissue of freshwater fish, tilapia (*Oreochromis mossambicus*). *Experimental Toxicology and Pathology*, 65: 903-909.
- Altwaitry N., Khan M.S., Shaik G.M., Tarique M., Javed

- M. (2023). Redox status, immune alterations, histopathology, and micronuclei induction in *Labeo rohita* dwelling in polluted river water. *Archives of Environmental Contamination and Toxicology*, 84: 179-187.
- Andersen Ø., Frantzen M., Rosland M., Timmerhaus G., Skugor A., Krasnov A. (2015). Effects of crude oil exposure and elevated temperature on the liver transcriptome of polar cod (*Boreogadus saida*). *Aquatic Toxicology*, 165: 9-18.
- Asatiani V.S. (1969). Manual book of enzyme detection. Nauka, Moscow. (in Russian)
- Ballesteros M.L., Rivetti N.G., Morillo D.O., Bertrand L., Amé M.V., Bistoni M.A. (2017). Multi-biomarker responses in fish (*Jenynsia multidentata*) to assess the impact of pollution in rivers with mixtures of environmental contaminants. *Sciences of the Total Environment*, 595: 711-722.
- Bhat R.A., Saoca C., Cravana C.F., Guerrero M.C., Labh S.N., Kesbiç O. (2023). Effects of heavy pollution in different water bodies on male rainbow trout (*Oncorhynchus mykiss*) reproductive health. *Environmental Sciences and Pollution Research*, 30: 23467-23479.
- Brown-Peterson N.J., Wyanski D.M., Saborido-Rey F., Macewicz B.J., Lowerre-Barbieri S.K. (2011). A standardized terminology for describing reproductive development in fishes. *Marine Coastal Fisheries: Dynamics, Management, and Ecosystem. Science*, 3: 52-70.
- Cerqueira C.C.C., Fernandes M.N. (2002). Gill tissue recovery after copper exposure and blood parameter responses in the tropical fish *Prochilodus scrofa*. *Ecotoxicology and Environmental Safety*, 52: 83-91.
- Corriero A., Zupa R., Mylonas C.C., Passantino L. (2021). Atresia of ovarian follicles in fishes, and implications and uses in aquaculture and fisheries. *Journal of Fish Diseases*, 44: 1271-1291.
- Çulha S.T., Yabanlı M., Birol Baki B., Yozukmaz A. (2016). Heavy metals in tissues of scorpion fish (*Scorpaena porcus*) caught from Black Sea (Turkey) and potential risks to human health. *Environmental Science and Pollution Research*, 23: 20882-20892.
- Dane H., Şişman T. (2020a). Effects of heavy metal pollution on hepatosomatic index and vital organ histology in *Alburnus mossulensis* from Karasu River. *Turkish Journal of Veterinary Animal Sciences*, 44(3): 607-617.
- Dane H., Şişman T. (2020b). A morpho-histopathological study in the digestive tract of three fish species influenced with heavy metal pollution. *Chemosphere*, 242: 125212.
- Dane H., Şişman T. (2021). Determination of oxidative, genotoxic, and histopathologic effects of metal pollution on the fish fauna inhabiting Karasu River, Turkey. *Turkish Journal of Zoology*, 45(7): 505-516.
- Dane H., Şişman T. (2023). The gonadal health status of Cyprinidae fish species collected from the river impacted by anthropogenic activities. *Su Urunleri Dergisi*, 40(4): 6-285.
- Erdoğan K. (2023). Determination of acute toxicity of sodium pyriothione and its exposure effects on antioxidant enzymes activity, immune status, and histopathological changes in common carp. *Chemistry and Ecology*, 39(4): 376-392.
- Eremeev V.N., Mironov O.G., Alemov S.V., Burdiyan N.V., Shadrina T.V., Tihonova E.A., Volkov N.G., Istomina M.I. (2008). Preliminary results of the evaluation of oil pollution of Kerch strait after the ships accidents Nov, 11 2007. *Marine Ecology Journal*, 7(3): 15-24. (in Russian)
- Feist S.W., Stentiford G.D., Kent M.L., Ribeiro Santos A., Lorange P. (2015). Histopathological assessment of liver and gonad pathology in continental slope fish from the northeast Atlantic Ocean and *Marine Environment Research*, 106: 42-50.
- Ferri J., Staglici N., Matic-Skoko S. (2012). The black scorpionfish, *Scorpaena porcus* (Scorpaenidae): Could it serve as reliable indicator of Mediterranean coastal communities' health? *Ecological Indicators*, 18: 25-30
- Folomeev V.F. (1981). Photocolometric ultramicromethod of the quantity determination of SH groups in the proteins and non-protein compounds on the blood. *Labor Delo*, 1: 33-35. (in Russian)
- Gashkina N.A., Moiseenko T.I., Shuman L.A., Koroleva I.M. (2022). Biological responses of whitefish (*Coregonus lavaretus* L.) to reduced toxic impact: metal accumulation, haematological, immunological, and histopathological alterations. *Ecotoxicology and Environmental Safety*, 239: 113659.
- Goldberg D.M., Sparner R.J. (1987). Glutathione reductase. In: Bergmeyer HU, Bergmeyer J., Grab M. (Eds.), *Methods of enzymatic analysis*. Verlag Chemie, Weinheim, 3: 258-265.
- Guerrera M.C., Aragona M., Porcino C., Fazio F., Laurà R., Levanti M., Montalbano G., Germanà G., Abbate F.,

- Germanà A. (2021). Micro and nano plastics distribution in fish as model organisms: histopathology, blood response and bioaccumulation in different organs. *Applied Sciences*, 11: 5768.
- Gurov K.I., Ovsyany E.I., Kotelyanets E.A., Konovalov S.K. (2015). Factors of formation and features of physical and chemical characteristics of bottom sediments in the Balaklava Bay (the Black Sea). *Physical Oceanography*, 46: 53-58. (in Russian)
- Gusso-Choueri P.K., Choueri R.B., de Araújo G.S., Cruz A.C.F., Stremel T.O.R., de Campos S.X., de Souza Abessa D.M., de Oliveira Ribeiro C.A. (2022). Univariate or multivariate approaches for histopathological biomarkers in the context of environmental quality assessments? *Marine Pollution Bulletin*, 181: 113828.
- Halafyan A.A. (2008). *STATISTICA 6. Data statistic processing. Chapter 8. Analysis of Variance. Binom, Moscow*. pp: 133-152. (in Russian)
- Hussain S., Sultana T., Sultana S., Hussain B., Mahboob S., Al-Ghanim K.A., Riaz M.N. (2021). Seasonal monitoring of river through heavy metal bioaccumulation and histopathological alterations in selected fish organs. *Journal of King Saud University – Science*, 33: 101626.
- Javed M., Ahmad M.I., Usmani N., Ahmad M. (2017). Multiple biomarker responses (serum biochemistry, oxidative stress, genotoxicity and histopathology) in *Channa punctatus* exposed to heavy metal loaded waste water. *Science Reports*, 7(1): 1-11.
- Kadim M.K., Risjani Y. (2022). Biomarker for monitoring heavy metal pollution in aquatic environment: an overview toward molecular perspectives. *Emerging Contaminants*, 8: 195-205.
- Khan R.A. (2011). Chronic exposure and decontamination of a marine sculpin (*Myoxocephalus scorpius*) to polychlorinated biphenils using selected body indices, blood values, histopathology and parasites as bioindicators. *Archives Environmental Contamination and Toxicology*, 60: 479-485.
- King Heiden T.C., Struble C.A., Rise M.L., Hessner M.J., Hutz R.J., Carvan M.J. (2008). Molecular targets of 2,3,7,8-tetrachlorodibenzo-p-dioxin (TCDD) within the zebrafish ovary: Insights into TCDD-induced endocrine disruption and reproductive toxicity. *Reproductive Toxicology*, 25(1): 47-57.
- Kostova S.K., Plotitsina O.V. (2011). Chemoecological studies of the mercury along the Black Sea Crimean coasts. In: *Chemical education in the context of the chemical safety: state of the problem and perspectives. Abstracts of the International Scientific Conference. Kiev: National Pedagogical University named M.P. Dragomanov*, 64-66. (in Russian)
- Kotelyanets E.A., Gurov K.I., Tikhonova E.A., Kondratev S.I. (2019). Pollutants in bottom sediments in the Balaklava Bay (the Black Sea). *Physical Oceanography*, 26(5): 414-424.
- Kuftarkova E.A., Rodionova N.U., Gubanov V.I., Bobko N.I. (2008). Hydrochemical characteristics of several Sevastopol bays. *Proceedings of UGNIRO*, 46: 110-117. (in Russian)
- Kumar N., Bhushan S., Gupta S.K., Kumar P., Chandan N.K., Singh D.K., Kumar P. (2021). Metal determination and biochemical status of marine fishes facilitate the biomonitoring of marine pollution. *Marine Pollution Bulletin*, 170: 112682.
- Litvin F.F. (1981). Detection of peroxydase activity. In: *Laboratory manual of physicochemical methods in biology. Russia, Moscow State University, Moscow*. pp: 86-87. (in Russian)
- Lomakin P.D., Popov M.A. (2011). Oceanological characteristics and evaluation of the pollution of Balaklava Bay. *ECOSY-Hydrophysics, Sevastopol*. 184 p. (in Russian)
- Lowry O.H., Rosebrough N.J., Farr A., Randall R. (1951). Protein measurement with the Folin-phenol reagent. *Journal of Biological Chemistry*, 193: 165-175.
- Maharajan A., Kitto R., Paruruckumani P.S., Ganapiriya V. (2016). Histopathology biomarker responses in Asian sea bass, *Lates calcarifer* (Bloch) exposed to copper. *Journal of Basic Applied Zoology*, 77: 21-30.
- Malahova L.V., Malahova T.V. (2009). Persistent organic pollutants in the coastal waters and bays of Sevastopol V International. Conference. «Ecological problems of big and small cities and industrial zones», Saint-Petersburg, July, 7-9. pp: 120-121.
- Matrodzadeh M., Rahim Abdi R., Basir Z., Peyghan R. (2023). Histological and enzymatic study of the liver of Nile tilapia, *Oreochromis niloticus* during the replacement of blood powder instead of fish meal in the diet. *Journal of Oceanography*, 14(53): 69-78.
- Mezentseva I.V., Chaikina A.V., Klimenko N.P. (2003). Current level of the pollution of the waters of Balaklava Bay. *Ecological Safety of the Coastal and Shelf Zone of the Sea*, 8: 115-118. (in Russian)
- Mikodina E.V., Sedova M.A., Chmylevsky D.A. (2009).

- Histology for ichthyologists: experience and advice. VNIRO, Moscow. 112 p. (in Russian)
- Mironov O.G., Kiruhina L.N., Alemov S.V. (2003). Sanitary-biological aspects of the ecology of Sevastopol bays in XX century, Sevastopol: ECOSY-Hydrophysics. 185 p. (in Russian)
- Monfared A.L., Bahrami A.M., Hosseini E., Soltani S., Shaddel M. (2015). Effects of nano-particles on histopathological changes of the fish Journal of Environmental Health Science and Engineering, 13:62
- Monteiro S.M., Rocha E., Fontainhas-Fernandes A., Sousa M. (2008). Quantitative histopathology of *Oreochromis niloticus* gills after copper exposure. Fish Physiology, 73(6): 1376-1392.
- Montenegro D.M., González T., Hickey T., Rahnama M., Green S., Lear G. (2022). Assessing integrated biomarkers of triplefin fish *Forsterygion capito* inhabiting contaminated marine water - a multivariate approach. Chemosphere, 288(2): 132590.
- Moussa A.M., Ramadan H., Abdel-Khale M.A. (2022). The antioxidant defense capacities and histological alterations in the livers and gills of two fish species, *Oreochromis niloticus* and *Clarias gariepinus*, as indicative signs of the Batts drain pollution. Environmental Science and Pollution Research, 29: 71731-71741.
- Nekrasov I.S., Shuman L.A., Selyukov A.G. (2021). Morphofunctional status of the Mongolian grayling *Thymallus brevisrostris* in a mountain lake in the south of Eastern Siberia. Inland Water Biology, 14(2): 150-158.
- Nishikimi M., Rao N.A., Yagik K. (1972). The occurrence of superoxide anion in the reaction of reduced phenazine. Biochemical and Biophysical Research Communication, 46(2): 849-854.
- Orekhova N.A., Ovsyany E.I., Gurov K.I., Popov M.A. (2018.) Organic matter and grain-size distribution of the modern bottom sediments in the Balaklava Bay (the Black Sea). Physical Oceanography, 34(6): 523-533.
- Orso G., Imperatore R., Coccia E., Rinaldi G., Cicchella D., Paolucci M. (2023). A deep survey of fish health for the recognition of useful biomarkers to monitor water pollution. Environments, 10: 219.
- Osadchaya T.S. (2013). Oil hydrocarbons in the bottom sediments of the coastal waters of Sevastopol. Scientific research and their practical application. Modern state and ways of development <http://www.sworld.com.ua/index.php/ru/conference/the-content-of-conferences/archives-of-individual-conferences/oct-2013>
- Ovsyanyi E.I., Romanov A.S., Minkovskaya R.Y. (2001). The main sources of marine pollution in Sevastopol region. Ecological Safety of the coastal and shelf zone and complex use of shelf resources. Sevastopol: ECOSY-Hydrophysics, 138-152. (in Russian)
- Popov M.A., Chepygenko A.I., Eremin I.J. (2005). Determination of the concentrations and scale distribution of the pollutants in Balaklava Bay used hydrooptical methods in autumn period. Ecological Safety of the Coastal and Shelf Zone of the Sea, 12: 202-212. (in Russian)
- Peyghan R., Rezaie A., Hassani F., Abiavi F. (2021), Histopathological study of gill and fish treatment in Ichthyophthiriasis of white skirt tetra (*Gymnocorymbus ternetzi*). Iranian Veterinary Journal, 17(1): 106-110.
- Phadmacanty N.L.P.R., Yulianto R., Dina G., Wahyudewantoro S., Aisyah A., Prawira A.Y. (2023). Histopathological study of fish gills in Situ Cikaret and Situ Cilodong, West Java Institute, Aquatic Science International Conference. IOP Conf. Series: Earth and Environmental Science, 1191, 012006
- Rafrafi-Nouira S., El Kamel-Moutalibi O., Boumanza M., Reynaud C., Capapy C. (2016). Food and feeding habits of Black Scorpionfish, *Scorpaena porcus* (Osteichthyes: Scorpaenidae) from the Northern Coast of Tunisia (Central Mediterranean) Journal of Ichthyology, 56(1): 107-123.
- Rezakhani Sh., Mohammadzadeh F., Khara H., Bahri A.H., Ahmadnezhad M. (2020). Immunological, hematological, and histological responses in blood, spleen and gill of *Salmo caspius* juveniles exposed in different water temperatures. Iranian Journal of Fisheries Sciences, 19(6): 2925-2942.
- Rohani M.F. (2023). Pesticides toxicity in fish: histopathological and hemato-biochemical aspects: A review. Emerging Contaminants 9: 100234.
- Rudneva I.I. (1997). Blood antioxidant system of Black Sea elasmobranch and teleosts. Comparative Biochemistry and Physiology, 118: 255-260.
- Rudneva I.I., Rudyk M.P., Shepelevich V.V., Skivka L.M., Roslova N.N., Skuratovskaya E.N., Chesnokova I.I., Shaida V.G., Kovyreshina T.B. (2017). Response of marine fish liver on environmental pollution. In: G.E. Zaikov, L.I. Weisfeld, E.M. Lisitsyn, S.A. Bekuzarova (Eds.), Heavy metals and other pollutants in the environment: biological aspects. Apple Academic

- Press, pp.383-406.
- Ruttkay-Nedecky B., Nejdil L., Gumulec J., Zitka O., Masarik M., Eckschlager T., Stiborova M., Adam V., Kizek R. (2013). The role of metallothionein in oxidative stress. *International Journal of Molecular Sciences*, 14: 6044-6066.
- Salaro A.L., Silva S.B., Ferraz R.B., Jiménez L.G.S., Carneiro C.L.S., Quadros A.S.G., Machado J., Freitas M.B., Oliveira E.E. (2023). Acute sublethal exposure to ethiprole impairs physiological and oxidative status in the Neotropical fish *Astyanax altiparanae*. *Environmental Pollution*, 334: 122152.
- Sangur K., Leiwakabessy F., Tuaputty H., Tuwankotta L.V., Samloy S.V., Ratila C., Salakory O.B., Matulesy C., Rumahlatu D. (2021). Mudskipper as an indicator species for lead, cadmium and cuprum heavy metal pollution in the Mangrove, Ambon, Indonesia. *Journal Ecological Engineering*, 22(4): 1-19.
- Santos D., Luzio A., Felix L., Bellas J., Monteiro S.M. (2022a). Oxidative stress, apoptosis and serotonergic system changes in zebrafish (*Danio rerio*) gills after long-term exposure to microplastics and copper. *Comp Biochem Physiol Part C: Toxicology and Pharmacology*, 258: 109363
- Santos R.M.B., Monteiro S.M.V., Cortes R.M.V., Pacheco F.A.L., Fernandes L.F.S. (2022b). Seasonal differences in water pollution and liver histopathology of Iberian Barbel (*Luciobarbus bocagei*) and Douro Nase (*Pseudochondrostoma duriense*) in an Agricultural Watershed. *Water*, 14: 444.
- Santos I.G.S., Lira A.S., da Silva Montes C., Point D., Médiou A., do Nascimento C.W.A., Lucena-Frédou F., da Rocha R.M. (2023). Revealing the environmental pollution of two estuaries through histopathological biomarkers in five fishes from different trophic guilds of northeastern Brazil. *Marine Pollution Bulletin*, 192: 115095
- Saoca C., Arfuso F., Giannetto C., Piccione G., Fazio F. (2023). Seasonal biodistribution of some trace elements (Cd, Pb, Cr, Hg) and “blood biomarkers” response in *Mugil cephalus* (Linnaeus, 1758). *Biological Trace Elements Research*, 201: 1987-1995.
- Sayed A.E.D.H., Idriss S.K., Abdel-Ghaffar S.K., Hussein A.A.A. (2023). Haemato-biochemical, mutagenic, and histopathological changes in *Oreochromis niloticus* exposed to BTX. *Environmental Science and Pollution Research*, 30: 59301-59315.
- Selyukov A.G. (2012). Morphofunctional transformations in fishes of the Middle and Lower Ob' basin under Increasing anthropogenic influence. *Journal of Ichthyology*, 52 (8): 547-565.
- Selyukov A.G., Zhigileva O.N., Borichevskaya A.I., Shadrina S.S. (2022). Assessment of the state of the populations of two fish species *Siganus fuscescens* (Houttuyn, 1782) and *Gerres oblongus* (Cuvier, 1830) (Actinopterygii: Perciformes Perciformes) in the sublittoral zone of Malapascua Island (Philippines). *Russian Journal of Marine Biology*, 48: 474-477.
- Sergeeva N.G., Kolesnikova E.A., Mazlumyan S.A. (2010). Taxonomic biodiversity of meiobentos in Sevastopol bays (Crimean coast of Black Sea) In: Biodiversity and sustainable development. Proceedings of Scientific conference May, 19-22, 2010. Russia, Simpheropol. pp: 113-115 (in Russian)
- Shuman L.A., Selyukov A.G., Nekrasov I.S., Kyrov D.N. (2019). Histopathology and changes of reproductive parameters in peled, *Coregonus peled*, from the Lower Ob basin. *Russian Journal of Ecology*, 50(4): 372-383.
- Şirin M., Bayrak E.Y., Baltaş H. (2024.) Human health risk assessment of heavy metals accumulation in different genders and tissues of whiting fish (*Merlangius merlangus euxinus* Nordmann, 1840) from Rize, Turkey. *Journal of Food Composition Analysis*, 127: 105971,
- Sitja-Bobadilla A. (2009). Review: Can myxosporean parasites compromise fish and amphibian reproduction? *Proceedings of the Royal Society B: Biological Sciences*, 276: 2861-2870.
- Solov'eva O.V., Tikhonova E.A. (2018). The organic matter content dynamics in the sea bottom sediments of the Sevastopol harbor water area. *Scientific Reports of Crimean Federal University named VI Vernadskyi, Biology, Chemistry*, 4(70): 196-206. (in Russian)
- Summerfelt R.C., Goodwin A.E. (2006). 3.2.3 Ovipleistophoriosis: A microsporidian disease of the golden shiner ovary 3.2.3 Ovipleistophoriosis, 1: 17 p.
- Temiz Ö., Kargin F. (2022). Toxicological impacts on antioxidant responses, stress protein, and genotoxicity parameters of aluminum oxide nanoparticles in the liver of *Oreochromis niloticus*. *Biological Trace Elements Research*, 200: 1339-1346.
- Tikhonova E.A., Kotelyants E.A., Volkov N.G. (2018). Characteristics of bottom sediments in the coastal waters of Sevastopol at the case of Streletskaia Bay (Black Sea). *Ecological Safety of Coastal and Shelf Zone of the Sea*, 1: 74-80. (in Russian)

- Turan F.M., Yilmaz B.M., Yola M.L., Ergenler A., Ilgaz N.S., Oksuz H. (2022). Bioaccumulation of trace metals and genotoxicity responses in *Liza aurata* as an indicator of industrial pollution. *Ecotoxicology*, 31: 1390-1402.
- Ulas A.E. (2022). Environmental impacts of the offshore drilling activities in the Black Sea. *GiDB DERGi Sair*, 22: 33-44.
- Yedier S., Bostanci D. (2021a). Intra-and Inter-species discriminations: *Scorpaena* species from the Black Sea, Aegean Sea, Sea of Marmara and Mediterranean Sea. *Scientia Marina*, 85(3): 197-209.
- Yedier S., Bostanci D. (2021b). Morphologic and morphometric comparisons of sagittal otoliths of five *Scorpaena* species in the Sea of Marmara, Mediterranean Sea, Aegean Sea and Black Sea. *Cahiers de Biologie Marine*, 64(4): 357-369.
- Zaman M., Khalil S.M.I., Rahman M.Z., Hossain A., Mamun M.A.A., Rahman M., Alam M.M.M. (2023). Evaluation of histopathological alterations in the liver and kidney of olive barb (*Puntius sarana*, Hamilton 1822) as an Indicator of the Surma River's Pollution. *Aquatic Science Engineering*, 38(2): 81-88.