

Original Article

Descriptive osteology of the vertebral column of Giant Trevally (*Caranx ignobilis* Forsskål, 1775) harvested from Aceh Province, Indonesia

Yusrizal Akmal^{*1}, Muliari Muliari², Ilham Zulfahmi³, Andi Iqbal Burhanuddin⁴, Yeni Dhamayanti⁵, Agung Setia Batubara⁶

¹Department of Aquaculture, Faculty of Agriculture, Universitas Almuslim, Bireuen, Indonesia.

²Department of Marine Sciences, Faculty of Agriculture, Universitas Malikussaleh, Aceh Utara, Indonesia.

³Department of Fisheries Resources Utilization, Faculty of Marine and Fisheries, Universitas Syiah Kuala, Banda Aceh, Indonesia.

⁴Department of Marine Sciences, Faculty of Marine Sciences and Fisheries, Hasanuddin University, Indonesia.

⁵Department of Veterinary Anatomy, Faculty of Veterinary Medicine, Airlangga University, Indonesia.

⁶Department of Biology, Faculty of Mathematics and Natural Sciences, Universitas Negeri Medan, Indonesia.

Abstract: We report a detailed description of the vertebral column of the giant trevally (*Caranx ignobilis*, Forsskål 1775). A total of 10 giant trevally were obtained from the Jangka seawaters, Bireuen Regency, Aceh Province, Indonesia. The giant trevally vertebral columns were processed physically and chemically. The vertebral column was disarticulated and observed individually. Morphometric parameters were measured, including the length, width, and height of the centrum, the length of the rib, the length of the neural spine, and the length of the haemal spine. The results showed that the vertebral column of the giant trevally consisted of three regions, namely the abdominal vertebrae, the caudal vertebrae, and the urostyle. The abdominal region comprises 10 centra, 7 pairs of costae, 10 neural spines, and 4 haemonephrophysis. The caudal region comprises 13 centra, 13 neural spines, 13 haemal spines, and 1 haemonephrophysis. The urostyle region is composed of 2 hypurals, 1 parhypural, 1 uroneural, and 1 epural. Morphometrically, the length and height value of the centrum of the giant trevally were greater than the width. The 4th costae, 14th neural spines, and 11th haemal spines were also observed to be the longest compared to others in their respective series.

Article history:

Received 29 July 2023

Accepted 4 December 2023

Available online 25 February 2024

Keywords:

Abdominal vertebrae

Caudal vertebrae

Urostyle

Costae

Haemal spine

Neural spine

Introduction

The Carangidae is an economically valuable fish family (Willette and Padin, 2014; Batubara et al., 2017; FAO, 2020). Damerou et al. (2018) determined that the Carangidae is divided into four subfamilies, 32 genera, and 146 species. Their habitat includes tropical, subtropical, marine, and brackish waters (Dekar et al., 2018; Irhami et al., 2018). Carangids have an elongated compressed body shape, a separate dorsal fin, two anterior spines on the anal fin, a narrow tail, and a caudal fin that is divided into two parts (homocercal) (Honebrink, 2000).

One carangid that has been widely studied is the genus *Caranx* (Damerou et al., 2018). *Caranx* has a large body with a slim body shape, 20-31 gill rakers in the first-gill arch, seven spines on the dorsal fin, and one to two spines on the anal fin (Torres and Santos, 2019). Maherung et al. (2017) report that up to now,

18 species have been attributed to the genus *Caranx*. Furthermore, White et al. (2013) revealed that there are five species of fish of the genus *Caranx* that inhabit Indo-Pacific waters, namely *Caranx ignobilis*, *C. melampygus*, *C. papuensis*, *C. sexfasciatus*, and *C. tille*.

The giant trevally (*C. ignobilis* Forsskål, 1775) is one of the target taxa for Indonesian fishermen (Fig. 1). This fish is reported to have a total length of up to 170 cm with a weight of up to 80 kg (Randall, 1995). The giant trevally is generally found in coastal waters ranging from a depth of less than 20 to 100 m (Sudekum, 1991). The population of giant trevally continues to decline due to high market demand accompanied by more catching efforts (Torres and Santos, 2019; FAO 2020).

Willette and Padin (2014) state that one of the challenges faced in identifying species in this genus is

*Correspondence: Yusrizal Akmal
E-mail: drh.yusrizal.akmal.msi@gmail.com




Figure 1. Lateral view of giant trevally (*Caranx ignobilis*) (Scale bar = 2 cm).

the presence of significant morphological changes between the juvenile and adult phases. For example, the juvenile phase of the giant trevally has a silvery-brown-yellow color, accompanied by five to six dark vertical lines on the lateral side of the fish. Conversely, the adult phase of the giant trevally has a turquoise silver color on the dorsal side and silvery-white on the ventral side (Lin and Shao, 1999). In addition, this taxon can also change color depending on the environmental conditions of the waters (Phuong et al., 2015). This phenomenon has caused taxonomic confusion among researchers (Jaafar et al., 2012). Efforts to further identify differences between species of the genus *Caranx* have been carried out through the study of comparative geometric morphometrics and DNA barcoding (Torres and Santos, 2019). However, identification efforts based on variations in the skeletal structure of this genus are rare. Hilton (2011) and Batubara et al. (2021) state that studies on the osteological morphology of fishes are urgently needed to present accurate information related to ontogeny, phylogeny, and ecomorphological concepts of fishes.

Several studies related to fish osteology in the Carangidae family have been published in the past, including the morphology of the vertebral column of *Carangoides caeruleopinnatus* (Jawad, 2015), the morphology of the anal fin of *Parastromateus niger* (Springer and Smith-Vaniz, 2008; Hilton et al., 2010), the morphology of the caudal vertebrae in *Caranx crysos* (Hilton and Johnson, 2007), and the osteology of *Trachinotus ovatus* (Zheng et al., 2016). There are no previously published studies related to the

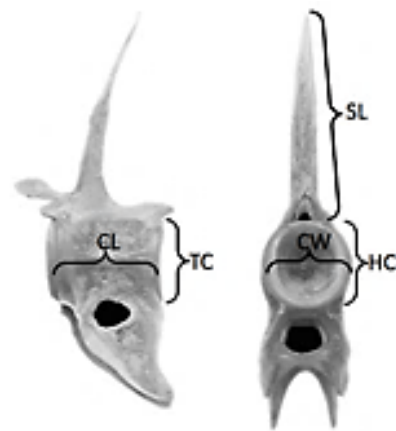


Figure 2. Morphometric parameters of the giant trevally's vertebral. CL: centrum length; CH: centrum height; CW: centrum width and SL: spinae length.

osteology of the giant trevally.

The vertebral column plays an important role in supporting the flexibility and elasticity of fish during movement (Jalili et al., 2015a; Zulfahmi et al., 2018). In addition, the vertebrae column also plays a role in the regulation and storage of phosphorus for homeostasis (Webb, 1975; Skonberg et al. 1997). In general, the vertebral column consists of five regions, namely the skull, abdominal vertebrae, caudal vertebrae, and urostyle (Nasri et al., 2016; Zulfahmi et al., 2019). According to Zulfahmi et al. (2018), studies related to the vertebral column of fishes are needed to understand the balance and acceleration of fish, among other reasons. Our research aims to describe the vertebral column morphology of the giant trevally.

Materials and Methods

A total of 10 giant trevally were obtained from

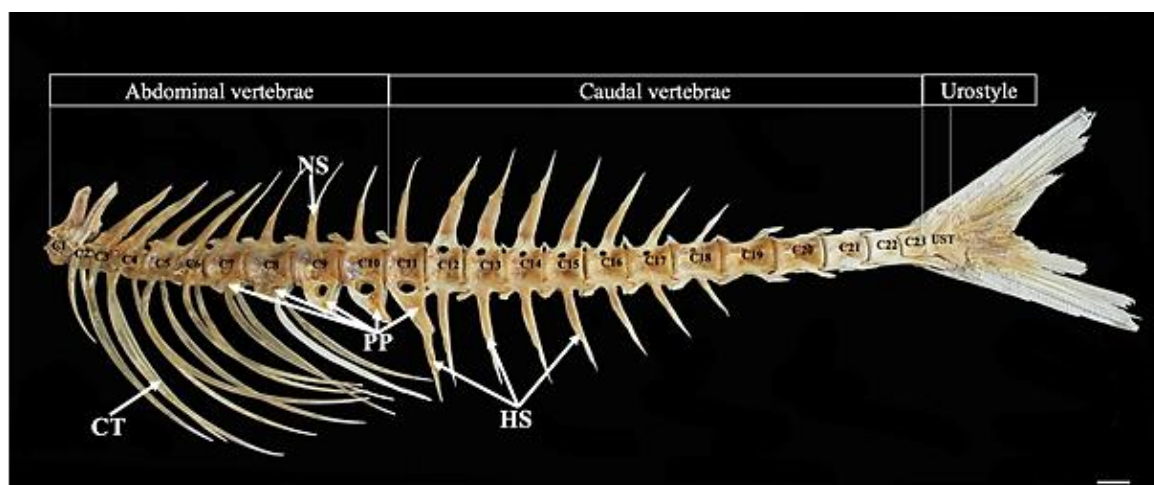


Figure 3. Lateral view of main regions of the giant trevally vertebral column (abdominal vertebrae, caudal vertebrae and urostyle). CT: costae; PP: parapophysis; HS: haemal spine; NS: neural spine (Scale bar = 2 cm).

fishermen in the Jangka estuary region, Bireuen Regency, Aceh Province, Indonesia ($5^{\circ}15'31.8''N$ $96^{\circ}47'07.4''E$). The weight of the specimens ranged between 2.2-3.1 kg, while their total length ranged between 38-46 cm. Our methodology can be broken into three stages: The preparation of the skeletons, the taking of morphometric measurements, and the identification of vertebral column regions. All processes of the study were conducted at the Mathematics and Natural Sciences Laboratory, Almuslim University, Indonesia.

Preparation of the vertebral column: Fish vertebral columns were prepared physically and chemically according to Zufahmi et al. (2018) and Batubara et al. (2021). The physical stage begins by removing muscle tissue and scales so that the vertebral column is visible. The anterior articulation of the first vertebrae was then separated from the cranium, and the costae (ribs) were detached, counted, and glued back into their original articulation.

Chemical preparation stages include soaking the vertebral column in a 10% formalin solution for seven days, followed by a 100% ethanol solution for 24 hours. Bone preparations are again cleaned using a brush with soft bristles to remove the remnants of muscle that were still attached to the bone preparations. The prepared vertebral column is sundried for seven days to remove its fat content. The prepared bone is then coated with varnish and dried again for three days.

Morphometric measurement of the vertebral column: Morphometric characteristics of the vertebral column measured, including the length, width, and height of the centrum, the length of the neural spines, and the length of the haemal spines. Centrum length was considered to be represented by the maximal distance between anterior and posterior articular surfaces, width measurements were considered to be the maximal distance between right and left lateral sides, while the measurement of the centrum height was considered to be the maximal distance between dorsal and ventral surfaces (Fig. 2). The length of the vertebral column is measured from the anterior articular surface of the first centrum to the posterior tip of the urostyle. Measurements were taken to the nearest 0.1 mm, using digital calipers. The measurements did not take the elements' curvature into account. Morphometric ratio values were obtained by comparing each measurement with the total length of the vertebral column. The formula used is $MR = M/\text{total length of the vertebral column}$, where MR is the morphometric ratio and M is the morphometric characters.

Photography, image editing, and identification of vertebral column regions: Every part of the vertebral column was photographed using a Canon EOS 700D camera, and image editing was conducted using Adobe Photoshop CS6. The vertebral column regions were determined by comparison of the shape and location of each bone with the vertebral column

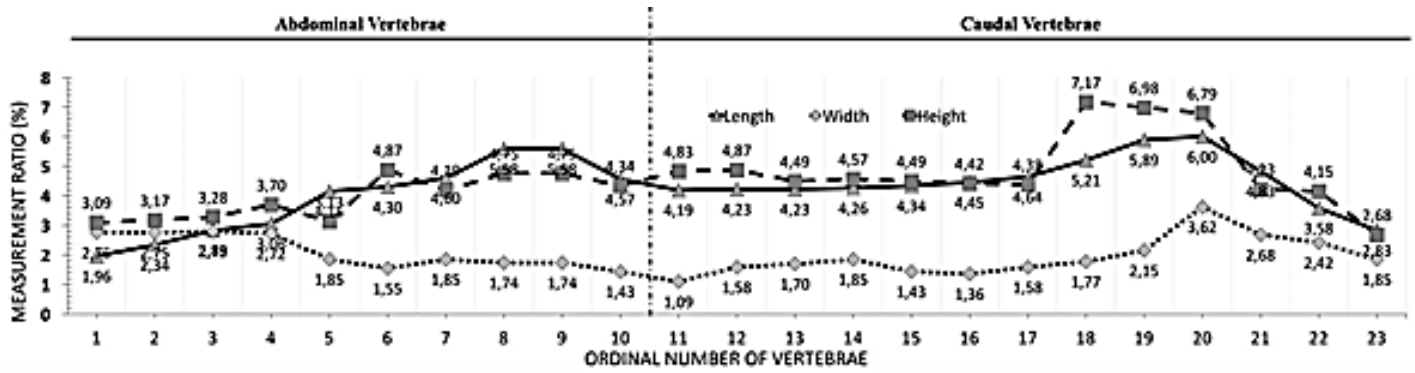


Figure 4. Length, height and width ratio centrum of the giant trevally.

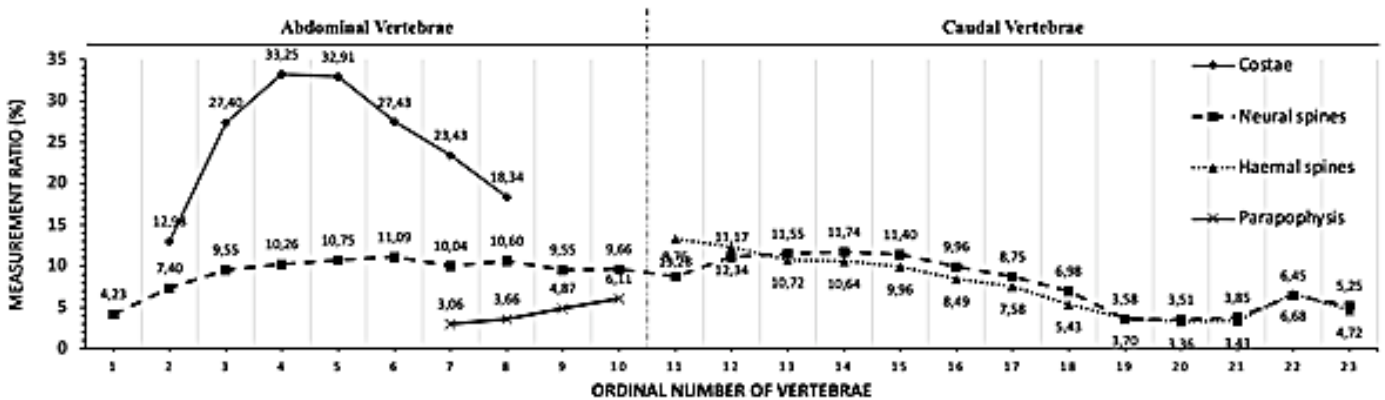


Figure 5. The ratio of costae, parapophysis, neural spine, and haemal spine length of the giant trevally.

morphology of different fish taxa that were previously studied by Rojo (1991), Huysentruyt and Adriaens (2005), Rojo (2013), Birindelli (2014), and Hasanpouret al., (2015). The data were presented in figures to be analyzed quantitatively and descriptively.

Results

The vertebral column of the giant trevally is divided into three main regions, namely the abdominal vertebrae, caudal vertebrae, and urostyle (Fig. 3). Ten vertebrae make up the abdominal series, comprising ten vertebral centra, seven pairs of pleural ribs, ten neural spines, and four haemonephropophysis. The caudal region includes 13 centra, 13 neural spines, 13 haemal spines, and one haemonephropophysis. The urostyle region consists of two hypurals, one parhypural, one uroneural, and one epural.

The giant trevally has a ratio of the length and height of the centrum which is greater than the width of the centrum. In general, the ratios of the length and

height of the centrum compared to the full length of the vertebral series tend to increase in the posterior abdominal vertebrae and caudal vertebrae. The 20th centrum has the largest centrum length-to-length of the vertebral series ratio, while the first centrum has the smallest ratio, with ratios of 6.00 and 1.96, respectively. The 18th centrum has the largest centrum height-to-length of the vertebral series ratio, while the 23rd centrum has the one, with ratios of 7.17 and 2.68, respectively. The centrum width-to-length of the vertebral series ratio tends to decrease in the posterior abdominal vertebrae and to increase again through the caudal vertebral series to reach higher values in the posterior caudal centra. The largest ratio is that of the 20th centrum, while the smallest width ratio is that of the 11th centrum, which are 3.62 and 1.09, respectively (Fig. 4).

The fourth pleural rib has the highest rib length-to-length of the vertebral series ratio, while the second rib has the smallest, with scores of 33.25 and 12.98, respectively. The ratio of the length of the neural and

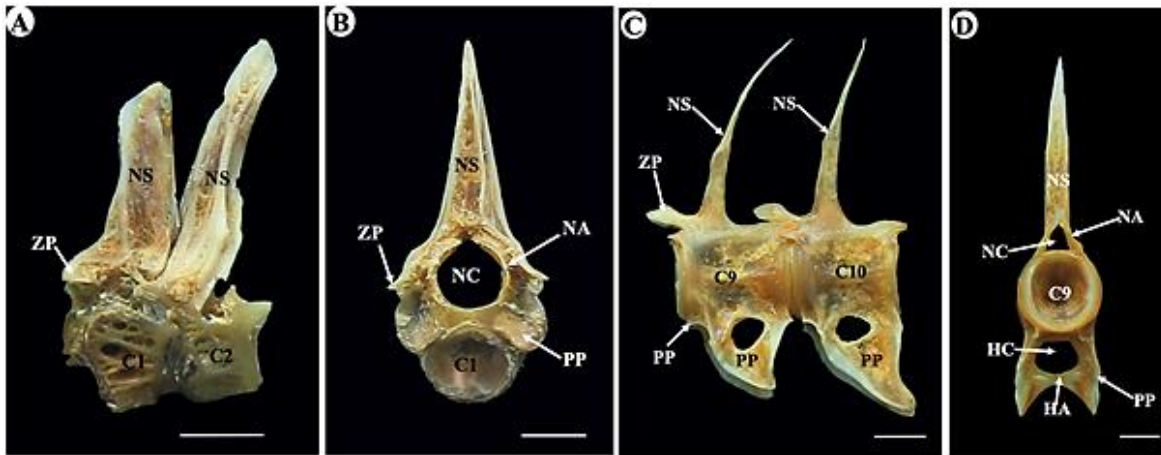


Figure 6. Lateral view of the anterior abdominal vertebrae region (A); Anterior view of the anterior abdominal vertebrae region (B); Lateral view of posterior abdominal vertebrae region (C); Anterior view of the anterior abdominal vertebrae region (D). C: centrum; HA: haemal arches; HC: haemal canal; NA: neural arches; NC: neural canal; NS: neural spine; PP: parapophysis; ZP: zygapophysis (Scale bar = 0.5 cm.)

haemal spines to the length of the vertebral column tends to increase through the vertebral series to the anterior portion of the caudal vertebrae and to decrease progressively again in more posterior regions of the caudal series. The largest neural spine length ratio is that of the 14th neural spine, while the smallest one is that of the 20th centrum, which are 11.74 and 3.51, respectively (Fig. 5).

The 11th haemal spine has the largest spine length-to-total vertebral series length ratio value, while the 20th one has the smallest length ratio value, respectively corresponding to 13.28 and 3.36. The length of the haemonephropophysis to the total length of the vertebral series tends to increase from the posterior abdominal series to the anterior caudal vertebrae. The largest ratio is that of the 11th haemonephropophysis, while the smallest ratio is that of the 7th haemonephropophysis, at respectively 7.59 and 3.06 (Fig. 5).

Abdominal vertebrae: The first and second neural spines are thicker and shorter compared to other neural spines in the abdominal region (Fig. 6a). The third to the sixth neural spines are angled posteriorly. In contrast, the seventh to tenth neural spines are thinner but longer, with a more tapered tip compared to other neural spines. All pleural ribs of the giant trevally are located in the abdominal region. Five pairs of ribs are attached to the centrum, while two other pairs are attached to the haemonephropophysis. The first rib is shorter and slimmer, while the ribs are wider and

longer towards the middle of the series.

The giant trevally has five haemonephropophysis, and four of them are located in the abdominal region. The first and second haemonephropophysis extend ventrally from both sides at an obtuse angle. Meanwhile, the third and fourth haemonephropophysis resemble triangles with angles that point ventrally. The abdominal region has four ventral holes (foramina), which become progressively larger posteriorly (Figs. 3, 6c). Conversely, the neural canal gets smaller posteriorly. The first centrum has a more developed and wider zygapophysis than the other centra (Figs. 6a, b, c). The neural canal in the first centrum is circular, while the ninth centrum is triangular. Additionally, the first haemal arch and the beginning of the haemal canal occur on the ninth centrum.

Caudal vertebrae: The caudal region extends between the 11th and 23rd centra. The neural spines in the anterior caudal region have a wider base compared to other neural spines. The neural spine of the 11th centrum corresponds to the dorsal fin attachment. The haemal spines become progressively shorter in the more posterior regions of the vertebral series. The first haemal spine corresponds to the anal fin attachment (Figs. 7a, b). From the 19th to 22nd centrum, neural and haemal spines are directed posteriorly, to the point of being nearly parallel. Additionally, the neural and haemal arches tend to become progressively smaller in more posterior regions of the caudal series.

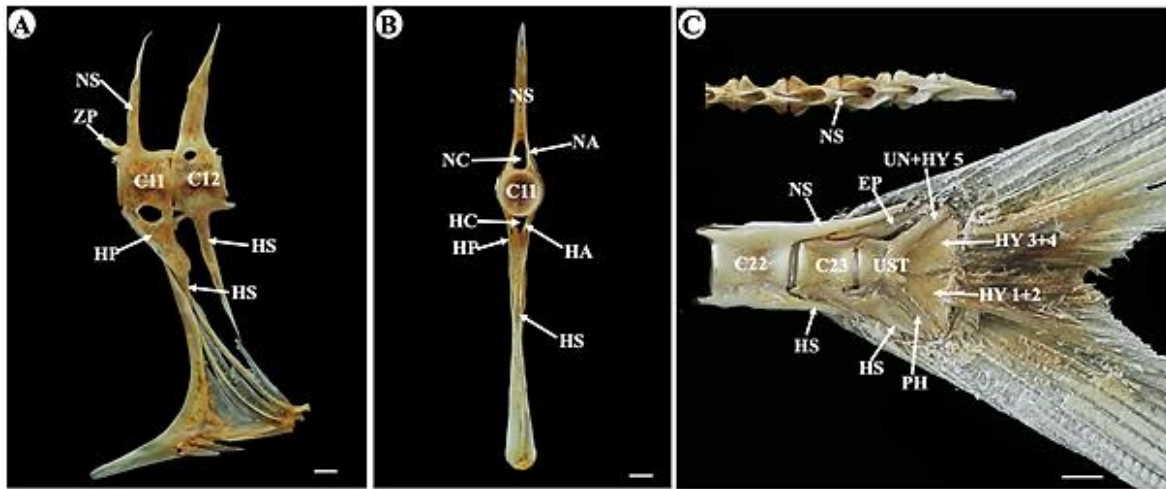


Figure 7. Lateral (A) and anterior (B) view of the anterior caudal vertebrae region; Lateral view of urostyle and posterior caudal vertebrae region (C). C: centrum; EP: epural; HA: haemal arches; HC: haemal canal; HP: haemonephropophysis; HS: haemal spine; HY: hypural; NA: neural arches; NC: neural canal; NS: neural spine; PH: parhypural; UN: uroneural; UST: urostyle; ZP: zygapophysis (Scale bar = 0.5 cm).

The only haemonephropophysis in this region is borne by the 11th centrum. The caudal region has one ventral vertebra and ten dorsal vertebrae foramen. The ventral vertebrae foramen is located in the 11th centrum, while the dorsal vertebrae foramen is located in the dorsal portion of the 12th to 21st centrum. The size of the dorsal vertebrate foramen tends to decrease in the posterior direction (Figs, 3, 7a).

Urostyle: The urostyle is located posterior to the 23rd centrum. There are five hypurals, which are divided into three groups, the 1st hypural is grouped with with the 2nd hypural, the 3rd hypural is grouped with the 4th hypural, and the 5th hypural is grouped with the uroneural. The epural and parhypural are elongated and thick. The epural lies parallel to the dorsal part of the urostyle. In the ventral region, there is a parhypural, while in the dorsal region, there is a uroneural (Fig. 7c).

Discussions

Studies related to vertebral column morphology are needed to understand kinematics (Day, 2002; Tyler et al., 2003), phylogenetic relationships, and fish functional systems (Jalili et al., 2015b; Sunger et al., 2020; Akmal et al., 2020; Akmal et al., 2022; Zulfahmi et al., 2022). In addition, fish vertebral elements show a high degree of interspecific variation allowing taxonomic identifications (e.g., Granadeiro and Silva, 2000; Jalili and Eagderi, 2014). Thus,

information related to vertebral column morphology can be used to describe the ontogeny of fish from the beginning of its development to adulthood (Adriaens et al., 2001; Farhang and Eagderi, 2019). Leprevost and Sire (2014) also explain how the morphological profile of the vertebral column greatly influences the speed and swimming style of various fish taxa.

The vertebral column of the giant trevally consists of three regions, namely the abdominal vertebrae, caudal vertebrae, and the urostyle. The abdominal and caudal regions consist of 11 and 13 centra, respectively. This distribution of centra among both vertebral regions is identical with several other carangids, such as *Trachicaranx tersus* (Prokofiev, 2002), *Parastromateus niger* (Hilton et al., 2010), and *Carangoides caeruleopinnatus* (Jawad, 2015). However, different families show various distributions of centra (e.g., Otero, 2004; Howellidae and Latidae; Prokofiev, 2007).

The most obvious difference between the giant trevally and the Otophysi is the absence of a Weberian apparatus. Nevertheless, the first and second centra of the giant trevally still have a size that is wider than any of the more posterior centra of the vertebral column. In addition, the swim bladder of giant trevally is not located at the front of the vertebrae column but is located closer to the dorsal part of the intestine (Katsuragawa, 1997). The increased sizes of the zygapophysis on the first and second centra and

parapophysis on the second centra are thought to function as the focal points of the lateral and ventral flexibility in the giant trevally.

The morphometric analysis of the centra shows that the length and height of the centra have greater ratio values than the width of the centra. Similar results were reported in other carangids, such as *C. caeruleopinnatus* (Jawad, 2015). Nevertheless, *C. caeruleopinnatus* tends to have centra with similar height and width ratios. Increasing length and height ratios of more posterior abdominal centra is thought to have a connection with the attachment of internal organs in the abdomen (Zulfahmi et al., 2019). The increase in the length and height ratios of the posterior caudal centra is related to the mechanical role of this region of the vertebral series, which acts in supporting the motion and acceleration of most fishes (Jawad, 2015). According to Oliver et al. (2016), each centrum that has a short size (length of vertebral centra) can affect and limit the mobility of each segment of the vertebral column.

Haemonephropophysis is a bone that extends ventrally from the centre in the posterior region of the abdominal vertebrae. In addition to the Carangidae, the presence of haemonephropophysis is also reported in the Pholidae (Sweetser and Hilton, 2016). Furthermore, according to Sweetser and Hilton (2016), the presence of haemonephropophysis indicates the presence of parts of the costae that are still not fully developed. Haemonephropophysis of the giant trevally began to develop at the 7th centrum, while in *Pholis laeta* from the family Pholidae, haemonephropophysis began to develop at the 3rd centrum (Sweetser and Hilton, 2016). Furthermore, studies related to haemonephropophysis in fish skeletal structures have not been widely reported.

The giant trevally has seven pairs of pleural ribs. This is the same number of ribs as are present in *Parastromateus niger* but is lower than in *Seriola dumerili* (8 pairs) (Liu, 2001; Hilton et al., 2010). The ribs function as a protective organ and support the formation of cavities in the abdominal region (Zulfahmi et al., 2018). The 4th rib has the largest rib length-to-length of vertebral series ratio. According to

Takeuchi and Hosoya (2011), the costal arch in fish is strongly influenced by the capacity of the abdominal cavity and the swimming style of the fish.

The ratio of the length of the neural spine to the haemal spine is largest for positions in the anterior caudal series. Spinal elevation occurs at the sites where the dorsal and anal fins are attached through pterygiophores (Jawad and Jig, 2017). This spinal structure may be related to expressing the locomotive function of the vertebral column (Ramzu et al., 1992). The first neural spine in the giant trevally is aligned upward. This is the same as in *Parastromateus niger* (Hilton et al., 2010), and unlike *Carangoides caeruleopinnatus*, where the tip of the neural spine leads anteriorly (Jawad, 2015). The neural spine height serves to increase the locomotory impulse. Swimming acceleration is mostly concentrated in the most caudal areas in carangids, so they need support for anatomical adaptation (Jawad, 2015).

The urostyle of the giant trevally is located posterior to the 23rd centrum. The giant trevally has a structure of urostyle region similar form to *Selene vomer* (Hilton and Johnson, 2007), but different from *Uylyaichthys eugeniae* (Prokofiev, 2002). Unlike other members of the Carangidae, such as *Caranx crysos*, mullet species, and *U. eugeniae*, who have two or three well-developed epurals (Prokofiev, 2002; Hilton and Johnson, 2007; Batubara et al., 2021), the giant trevally only has one epural. Based on these results, epural could be a specific character (interspecies morphotypes) in the genus *Caranx* in particular, because there are differences in numbers.

Conclusion

The vertebral column of the giant trevally consists of three regions: the abdominal and caudal regions, followed by a urostyle. The ratio of the length and height of the centrum of the giant trevally is higher than the centrum width ratio. The 4th rib has the highest length ratio, while the second rib has the lowest score. The largest length ratio is that of the 14th neural spine, while the smallest length ratio is that of the 20th neural spine. The 11th haemal spine has the highest length ratio value, while the 20th haemal spine

has the smallest length ratio value. The giant trevally has a spinal morphology that appears adapted to maximize swimming acceleration, especially horizontally.

Acknowledgments

Thank you to the Mathematics and Natural Sciences Laboratory of the Almuslim University, Bireuen Regency, for facilitating the use of space and supporting tools for this research. Thank you also to Chairun Nisa and Zulfikri for collaborating and sharing the same fate as assisting with the implementation of this research.

References

- Adriaens D., Aerts P., Verraes W. (2001). Ontogenetic shift in mouth opening mechanisms in a catfish (Clariidae, Siluriformes): a response to increasing functional demands. *Journal of Morphology*, 247: 197-216.
- Akmal Y., Zulfahmi I., Dhamayanti Y., Paujiah E. (2020). Osteocranium of *Tor tambroides* (Cypriniformes: Cyprinidae) from Tangse River, Aceh, Indonesia. *Biodiversitas*, 21: 442-450.
- Akmal Y., Muliari M., Humairani R., Zulfahmi I., Burhanuddin A.I., Budimawan B., Batubara A.S. (2022). Species authentication of *Tor* spp.(family Cyprinidae) in Indonesia based on osteocranium structure and biometric data. *Zoologischer Anzeiger*, 299: 21-30.
- Batubara A.S., Muchlisin Z.A., Thamren M.Y., Usnardi U., Fadli N. (2017). Check list of marine fishes from Simeulue Island waters, Aceh Province, Indonesia. *Aceh Journal of Animal Science*, 2: 77-84.
- Batubara A.S., Yulianto D., Muhammadar A.A., Dewiyanti I., Siti-Azizah M.N., Efizon D., Muchlisin Z.A. (2021). Skeletal structure as taxonomic tool for identification of mullet species (Teleostei: Mugilidae) from Aceh waters, Indonesia. *Journal of Applied Ichthyology*, 37(5): 697-705.
- Birindelli J.L.O. (2014). Phylogenetic relationships of the South American Doradoidea (Ostariophysi: Siluriformes). *Neotropical Ichthyology*, 12: 451-564.
- Damerau M., Freese M., Hanel R. (2018). Multi-gene phylogeny of jacks and pompanos (Carangidae), including placement of monotypic vadigo *Campogramma glaycos*. *Journal of Fish Biology*, 92(1): 190-202.
- Day J.J. (2002). Phylogenetic relationships of the Sparidae (Teleostei: Percoidei) and implications for convergent trophic evolution. *Biological Journal of the Linnean Society*, 76(2): 269-301.
- Dekar M., Sarong M.A., Batubara A.S., Muchlisin Z.A. (2018). Ichthyofauna of Aceh River, Aceh Province, Indonesia. *OP Conference Series: Earth and Environmental Science*, 216: 012024.
- FAO. (2020). *FAO fisheries and aquaculture statistics introduction*. Food and Agriculture Organization, Rome.
- Farhang P., Eagderi S. (2019). Skeletal ontogeny of the caudal complex in Caspian kutum, *Rutilus kutum* (Kamensky, 1901)(Teleostei: Cyprinidae) during early development. *Caspian Journal of Environmental Sciences*, 17(2): 113-119.
- Granadeiro J.P., Silva M.A. (2000). The use of otoliths and vertebrae in the identification and size-estimation of fish in predator-prey studies. *Cybium*, 24(4): 383-393.
- Hasanpour SH., Eagderi S., Mojazi Amiri B. (2015). Osteological development of the vertebral column, paired, dorsal and anal fins in *Rutilus caspicus*, Pravdin (1927) (Teleostei: Cyprinidae). *Caspian Journal of Environmental Sciences*, 13(3): 207-219.
- Hilton E.J., Johnson G.D. (2007). When two equals three: developmental osteology and homology of the caudal skeleton in carangid fishes (Perciformes: Carangidae). *Evolution and Development*, 9(2): 178-189.
- Hilton E.J., Johnson G.D., Smith-Vaniz W.F. (2010). Osteology and systematics of *Parastromateus niger* (Perciformes: Carangidae), with comments on the carangid dorsal gill-arch skeleton. *Copeia*, 2010(2): 312-333.
- Hilton E.J. (2011). *Bony fish skeleton*. Elsevier Inc. Virginia Institute of Marine Science, Gloucester Point, VA, USA. pp: 434-436.
- Honebrink R.R. (2000). A review of the biology of the family Carangidae, with emphasis on species found in Hawaiian waters. Division of Aquatic Resources, Department of Land and Natural Resources, USA.
- Huysentruyt F., Adriaens D. (2005). Descriptive osteology of *Corydoras aeneus* (Siluriformes: Callichthyidae). *Cybium*, 29(3): 261-273.
- Irhami S., Fithri A., Batubara A.S., Muchlisin Z.A. (2018). Fish fauna of Meureubo River, Aceh Barat District, Indonesia. *IOP Conference Series: Earth and Environmental Science*, 216: 012023.

- Jaafar T.N.A.M., Taylor M.I., Mohd-Nor S.A., de-Bruyn M., Carvalho G.R. (2012). DNA barcoding reveals cryptic diversity within commercially exploited Indo-Malay carangidae (Teleostei: Perciformes). *Plos One*, 7(11): e49623.
- Jalili P., Eagderi S. (2014). Osteological description of Iran cave barb (*Iranocypris typhlops* Bruun & Kaiser, 1944). *University Journal of Zoology, Rajshahi University*, 33: 01-07.
- Jalili P., Eagderi S., Nikmehr N., Keivany Y. (2015a). Descriptive osteology of *Barbus cyri* (Teleostei: Cyprinidae) from southern Caspian Sea basin. *Iranian Journal of Ichthyology*, 2(20): 105-112.
- Jalili P., Eagderi E., Nasri M., Mousavi-Sabet H. (2015b). Descriptive osteology study of *Alburnus amirkabiri* (Cypriniformes: Cyprinidae), a newly described species from Namak lake basin, central of Iran. *Bulletin of the Iraq Natural History Museum*, 13(4): 51-62.
- Jawad L.A. (2015). Study of the vertebral column of the onion trevally, *Carangoides caeruleopinnatus* (Teleostei: Carangidae) collected from the sea of Oman. *Italian Journal of Zoology*, 82(1): 41-47.
- Jawad L.A., Jig L. (2017). Comparative osteology of the axial skeleton of the genus *Pampus* (Family: Stromateidae, Perciformes). *Journal of the Marine Biological Association of the United Kingdom*, 97(2): 277-287.
- Katsuragawa M. (1997). Larval development of the Atlantic moonfish *Selene setapinnis* (Osteichthyes, Carangidae) from southeastern Brazil. *Bulletin of Marine Science*, 61(3): 779-789.
- Leprevost A., Sire J.Y. (2014). Architecture, mineralization and development of the axial skeleton in Acipenseriformes, and occurrences of axial anomalies in rearing conditions; can current knowledge in teleost fish help. *Journal of Applied Ichthyology*, 30(4): 767-776.
- Lin P.L., Shao K.T. (1999). A review of the carangid fishes (Family Carangidae) from Taiwan with descriptions of four new records. *Zoological Studies Taipei*, 38: 33-68.
- Liu C.H. (2001). Early osteological development of the yellow tail *Seriola dumerili* (Pisces: Carangidae). *Zoological Studies Taipei*, 40: 289-298.
- Maherung S.S., Bataragoa N.E., Salaki M.S. (2017). Size and food habit of travelly (*Caranx* spp.) in the intertidal zone around the field laboratory of Unsrat, Likupang. *Jurnal Ilmiah Platax*, 6(1): 6-11.
- Nasri M., Farahmand H., Eagderi S. (2016). Descriptive and comparative osteology of Bighead Lotak, *Cyprinion milesi* (Cyprinidae: Cypriniformes) from southeastern Iran. *Vertebrate Zoology*, 66: 251-260.
- Oliver J.D., Jones K.E., Hautier L., Loughry W.J., Pierce S.E. (2016). Vertebral bending mechanics and xenarthrous morphology in the nine-banded armadillo (*Dasypus novemcinctus*). *Journal of Experimental Biology*, 219(19): 2991-3002.
- Otero O. (2004). Anatomy, systematics and phylogeny of both recent and fossil latid fishes (Teleostei, Perciformes, Latidae). *Zoological Journal of the Linnean Society*, 141(1): 81-133.
- Phuong T.V., Anh H.T.V., Phuong L.T.N., Linh N.Q. (2015). Biological features and distribution of giant trevally (*Caranx ignobilis* Forsskal, 1775) in Tam Giang-Cau Hai Lagoon systems, Vietnam. *Critical Reviews in Environmental Science and Technology*, 5: 548-560.
- Prokofiev A.M. (2002). A remarkable new genus of Carangidae from the Upper Paleocene of Turkmenistan (Osteichthyes, Perciformes). *Zoosystematica Rossica*, 11(1): 219-228.
- Prokofiev A.M. (2007). Osteology of *Florenciella lugubris* (Percoidae: Epigonidae). *Journal of Ichthyology*, 47(9): 715-725.
- Ramzu M., Meunier F.J., Schovaer D. (1992). Morphological and histological characteristics of the vertebral axis zonation in the trout (*Salmo trutta* L.) (Teleostei, Salmonidae): possible functional implications. *Oceanis*, 18: 85-91.
- Randall J.E. (1995). *Coastal fishes of Oman*. University of Hawaii Press, USA. 439 p.
- Rojo I.L. (1991). *Dictionary of evolutionary fish osteology*. CRC Press, Florida, USA. 282 p.
- Rojo A. (2013). *Osteological atlas of the Brown Bullhead (Ameiurus nebulosus) from Nova Scotia waters: A morphological and biometric study*. Curatorial Report Number 100, Nova Scotia Museum, Halifax. 151 p.
- Skonberg D.I., Yogev L., Hardy R.W., Dong F.M. (1997). Metabolic response to dietary phosphorus intake in rainbow trout (*Oncorhynchus mykiss*). *Aquaculture*, 157(1-2): 11-24.
- Springer V.G., Smith-Vaniz W.F. (2008). Supraneural and pterygiophore insertion patterns in carangid fishes, with description of a new Eocene carangid tribe, †Paratrachinotini, and a survey of anterior anal-fin pterygiophore insertion patterns in Acanthomorpha. *Bulletin of the Biological Society of Washington*, 16(1):

1-73.

- Sudekum A.E. (1991). Life history and ecology of large jacks in undisturbed, shallow, oceanic communities. *Fish Bulletin*, 89: 493-513.
- Sungur S., Eagderi S., Jalili P., Çiçek E. (2020). Caudal osteology and its application to reconstruct phylogenetic relationship in the genus *Garra*. *Ege Journal of Fisheries and Aquatic Sciences*, 37(3): 245-249.
- Sweetser P.W., Hilton E.J. (2016). Osteology of the crescent gunnel *Pholis laeta* and the phylogeny of the family Pholidae (Cottiformes, Zoarcoidei). *Journal of Fish Biology*, 89(3): 1666-1691.
- Takeuchi H., Hosoya K. (2011). Osteology of *Ischikauia steenackeri* (Teleostei: Cypriniformes) with comments on its systematic position. *Ichthyological Research*, 58(1): 10-18.
- Torres S.K.M., Santos B.S. (2019). Species identification among morphologically-similar *Caranx* species. *Turkish Journal of Fisheries and Aquatic Sciences*, 20(2): 159-169.
- Tyler J.C., O'Tool B., Winterbottom R. (2003). Phylogeny of the genera and families of Zeiform fishes, with comments on their relationships with Tetraodontiforms and caproids. *Smithsonian Contribution to Zoology*. 618: 1-110.
- Webb P.W. (1975). Hydrodynamics and energetics of fish propulsion. *Bulletin of the Fisheries Research Board of Canada*, 190: 1-159.
- White W.T., Dharmadi D., Last P.R., Faizah R., Chodrijah U., Prisantoso B.I., Pogonoski J.J., Puckridge M. (2013). *Market fishes of Indonesia*. Australian Centre for International Agricultural Research, Australia. 438 p.
- Willette D.A., Padin J.I.M. (2014). Identifying the biodiversity of marine jacks (Carangidae) in the freshwater Taal Lake, Philippines using phenotypic features and mitochondrial DNA. *Journal of Applied Ichthyology*, 30(3): 490-495.
- Zheng P., Ma Z., Guo H., Zhang D., Fu M., Zhang N., Jiang S. (2016). Osteological ontogeny and malformations in larval and juvenile golden pompano *Trachinotus ovatus* (Linnaeus 1758). *Aquaculture Research*, 47(5): 1421-1431.
- Zulfahmi I., Akmal Y., Batubara A.S. (2018). The morphology of Thai mahseer's *Tor tambroides* (Bleeker, 1854) axial skeleton (*ossa vertebrae*). *Jurnal Iktiologi Indonesia*, 18(2): 139-149.
- Zulfahmi I., Akmal Y., Muliari M. (2019). Osteologi ikan Keureling (*Tor tambroides*). IPB Press, Bogor, Indonesia.
- Zulfahmi I., Akmal Y., Burhanuddin A.I., Dhamayanti Y., Paujiah E., Sumon K.A., Pandit D.N., Nur F.M. (2022). Osteocranium anatomy of African Catfish (*Clarias gariepinus* Burchell 1822) from cultured pond in Aceh, Indonesia. *Iraqi Journal of Veterinary Sciences*, 36(3): 549-554.