

Original Article

A histo-morphological characteristics of gonads in Mudskipper, *Periophthalmus waltoni* Koumans, 1941 from Helleh estuary, Southwestern Iran

Somayeh Ghasemian¹, Hamid Reza Esmaeili*¹, Mohsen Nokhbatolfoghahai¹, AbdolRahim Pazira²

¹Department of Biology, College of Sciences, Shiraz University, Shiraz, Iran.

²Department of Fisheries, Islamic Azad University, Bushehr Branch, Bushehr, Iran.

Abstract: In this study, the morphological and histological studies of male and female gonads in mudskipper, *Periophthalmus waltoni* Koumans, 1941 from Helleh estuary (Bushehr Province, southwestern Iran) were performed to determine its gonadal development stages and histo-morphological characteristics. Sampling was done from April 2010 to March 2011 and a total of 81 individuals were collected by hand net. The gonads of specimens were removed, their sexes determined and then fixed in 10% formalin solution after checking their morphology and measuring their weights, lengths and widths. Six stages of gonadal developments in females and four stages in males were determined based on macroscopic and microscopic observations and reproductive indices. In female, increasing of the ovary size is occurred because of the accumulation of yolk materials in oocytes, and in the last stages, little folding in ovary was observed. Formation of zona radiata and yolk granules in the third stage, and increasing thickness of this layer and yolk granules were observed from stage three to stage six. In male, gradual developments of the sperm cells were observed from stage one onward.

Article history:

Received 14 June 2015

Accepted 12 October 2015

Available online 25 December 2015

Keywords:

Gobiidae

Reproduction indices

Gonad histology

Iran

Introduction

There are sever debates on the taxonomic position of gobioid fishes at the order and family levels especially during the last few years. While most of the scientists consider these fishes in the order Perciformes, however, Thacker (2013) proposed Gobiiformes and Gobionellidae as distinct order and family. The family Gobionellidae was identified by Thacker (2003; there denoted the "expanded monophyletic Gobionellinae") and separated from Gobiidae (Thacker, 2009) as part of broad molecular phylogenetic analyses of the gobioid fishes (Order Gobiiformes; Thacker, 2013). That analysis delineated the family Gobionellidae composed of inshore, shallow-dwelling fishes, most of which are euryhaline; it includes stream gobies, mudskippers, and eel gobies, among others (Thacker, 2013). However, mudskippers has been considered in the order Perciformes (Perch-likes), family Gobiidae

(Gobies) and subfamily Oxudercinae (see Eschmeyer and Fong, 2015). Esmaeili et al. (2010) reported 40 species of the gobioid fishes from Iran including mudskippers. Mudskippers of Iran are member of the subfamily Oxudercinae (tribe Periophthalmini, Murdy, 1989), or *Periophthalmus* Lineage including *Periophthalmus*, *Boleophthalmus* and *Scartelaos* (Thacker, 2013). They are completely amphibious fish that can use their pectoral fins to "walk" on land (Harris, 1960; Swanson and Gibb, 2004). These fishes spend extensive periods of time out of water and have numerous physiological, morphological and behavioral specializations for amphibious life style (Gordon et al., 1969; Clayton, 1993; Graham, 1997; Lee and Graham, 2002). Walton's Mudskipper, *Periophthalmus waltoni* Koumans, 1941 (sensu Murdy, 1989) is a member of *Periophthalmus* lineage known from a variety of intertidal habitats, including mudflats and mangrove

* Corresponding author: Hamid Reza Esmaeili
E-mail address: hresmaeili22@gmail.com

ecosystems of the Persian Gulf and Makran Sea (Ghanbarifardi and Malek, 2007; Ghanbarifard et al., 2014a, b). Its distribution is from the western part of Persian Gulf to Pakistan (Murdy, 1989). Walton's mudskipper is not commercially valuable locally, but it is preyed by sea birds. It may play an important role as a bioindicator of anthropogenic impact on habitat in mangrove forests and intertidal areas (Wong et al., 2000; Polgar, 2008). Study on the gonadal development of *P. waltoni* is scarce. Therefore, this study was conducted to provide a detailed description of the gonadal development and histo-morphological characteristics of *P. waltoni* from Helleh estuary, Southwestern Iran.

Materials and Methods

A total of 81 individuals of Walton's Mudskipper, *P. waltoni* (Fig. 1) were collected by hand-net from Helleh estuary in Bushehr Province (29°09'23.9" N; 50°40'19" E, 2 m a.s.l), southwestern Iran between April 2010 to March 2011. After anesthesia, fish were fixed in 10% formalin, then labeled individually and deposited in the Zoological Museum, Collection of Biology Department, Shiraz University (ZM-CBSU). Some morphometric features were measured using digital caliper to the nearest 0.01 mm and body weights were determined using a digital balance to the nearest 0.1 g. The specimens were cut through the ventral position and gonads were taken out of the body, the sexes and stages of sexual maturation were determined as possible as by naked eye examination and under compound microscope.

A chi-square test was used to assess deviation from 50:50 sex ratio based on Robards et al. (1999). The gonads were then fixed into 10% formalin solution after checking their morphology and measuring their weights by a digital balance to the nearest 0.001 g, and the lengths and widths with a digital caliper at 0.01 mm.

The histological sections of the gonads were prepared by a routine histology method based on Bancroft and Stevens (1991) as follow: The gonads were dehydrated in alcohol, cleared in xylene, and



Figure 1. Walton's mudskipper, *P. waltoni*, from Helleh estuary, southwestern Iran.

impregnated in paraffin wax at 56°C melting point, sectioned at 5-7 μm thickness and then stained using Hemotoxylin and Eosin (H&E). After preparing the histological slides, they were studied under a compound microscope and the photos were taken. Sexual maturity of each specimen was classified according to macroscopic criterion based on ICES (International Council for Exploration of the Sea of 1963, 1999) and a microscopic criterion, based on morphological and histological analysis.

Results

Size range: A total of 81 individuals of *P. waltoni* ranging 49.81-125.88 mm (S.D: 15.38) in total length, 39.71-102.35 (S.D: 12.84) in standard length, and total weight of 0.85-17.35 g (S.D: 4.04) were collected.

Sex ratio: We determined sex in 50 female and 28 male specimens. The overall sex ratio was significantly female biased and deviates from the hypothetical distribution of 1:1 (1.8:1, f/m; Chi square=6.205, df=1, $P=0.01$).

The structure of ovaries: A pair of elongated ovaries were situated in the posterior of the gut and adhered to the vertebral column. Anteriorly, the two lobes are free but adjoined together posteriorly and ended to the genital pore. During gonadal development, the weight, length and width of ovary increased and its color changed from cream to dark yellow. The oocytes were observed easily from 3rd stage by naked eye.

Macroscopic and microscopic characteristics of ovaries: Macroscopically and microscopically the

Table 1. Comparison of the used maturity criterion in the present study with criterion used in ICES.

Maturity stages in the present study		Maturity stages used in ICES
Female	Male	
I. Immature	I. Immature	I. Virgin
II. Immature and Developing	II. Immature and Developing	II. Virgin maturing VII. Recovering-spent
III. Maturing	III. Maturing	III. Maturing
IV. Maturing	IV. Ripe	IV. Maturing
V. Ripe		V. Maturing
VI. Spawning		VI. Spawning
VII. spent		VII. Spent

Table 2. Descriptive statistics of gonad measurements in *P. waltoni* (female) from Helleh estuary, southwestern Iran.

Stage	Measurements	N	Mini	Max	Mean	SD
I	Gonad Weight (g)	1	0.002	0.002	0.00200	.
	Gonad length (mm)	1	8.38	8.38	8.3750	.
	Gonad Width (mm)	1	0.55	0.55	0.5483	.
	GL.ACL (%)	1	47.16	47.16	47.1565	.
II (early)	Gonad Weight (g)	23	0.001	0.027	0.01061	0.006236
	Gonad length (mm)	23	4.50	14.53	9.6293	2.19507
	Gonad Width (mm)	23	0.83	1.51	1.1910	0.21419
	GL.ACL	23	36.20	75.46	55.9532	9.30253
II (late)	Gonad Weight (g)	7	0.016	0.050	0.02529	0.011940
	Gonad length (mm)	7	8.88	13.47	11.0557	1.68212
	Gonad Width (mm)	7	1.25	1.84	1.5640	0.19575
	GL.ACL	7	49.58	71.33	59.6237	8.86275
III	Gonad Weight (g)	10	0.040	0.124	0.07210	0.032716
	Gonad length (mm)	10	10.32	14.19	11.7585	1.31446
	Gonad Width (mm)	10	1.68	2.61	2.1268	0.33231
	GL.ACL	10	51.72	72.18	62.1627	7.40175
IV	Gonad Weight (g)	4	0.185	0.330	0.23375	0.065749
	Gonad length (mm)	4	14.78	16.69	15.3238	0.91017
	Gonad Width (mm)	4	3.20	3.64	3.3967	0.18149
	GL.ACL	4	65.76	95.84	77.1354	13.19831
V	Gonad Weight (g)	4	0.620	0.680	0.64500	0.026458
	Gonad length (mm)	4	19.51	22.22	20.4800	1.26219
	Gonad Width (mm)	4	4.74	5.24	4.9275	0.24001
	GL.ACL	4	81.29	93.53	89.0697	5.41776
VI	Gonad Weight (g)	1	0.850	0.850	0.85000	.
	Gonad length (mm)	1	24.09	24.09	24.0900	.
	Gonad Width (mm)	1	5.24	5.24	5.2383	.
	GL.ACL	1	104.06	104.06	104.0605	.

GL.ACL: The ratio of gonad length to abdominal cavity length

Table 3. Descriptive statistics of Gonad measurements in *P. waltoni* (Male) from Helleh estuary, southwestern Iran.

Stage	Measurements	N	Min	Maxi	Mean	SD
1	Gonad Weight (g)	1	0.001	0.001	0.00100	.
	Gonad length (mm)	1	6.73	6.73	6.7300	.
	Gonad Width (mm)	1	0.41	0.41	0.4050	.
	GL.ACL (%)	1	63.37	63.37	63.3710	.
2	Gonad Weight (g)	7	0.001	0.001	0.00100	0.00
	Gonad length (mm)	7	7.02	9.57	8.2707	1.01745
	Gonad Width (mm)	7	0.37	0.52	0.4231	0.04715
	GL.ACL	7	46.75	69.35	61.5569	7.56434
3	Gonad Weight (g)	14	0.001	0.067	0.01157	0.018744
	Gonad length (mm)	14	4.05	12.96	8.5657	2.32659
	Gonad Width (mm)	14	0.36	1.32	0.7448	0.28723
	GL.ACL	14	23.67	58.55	44.4367	9.96509
4	Gonad Weight (g)	6	0.002	0.093	0.01983	0.035891
	Gonad length (mm)	6	7.02	10.54	9.0350	1.36054
	Gonad Width (mm)	6	0.68	1.30	1.0378	0.24428
	GL.ACL	6	35.45	62.16	48.4772	9.47384

GL.ACL: The ratio of gonad length to the abdominal cavity length.

ovaries were classified into seven developmental stages based on the size and weight, degree of occupation of the body cavity, presence or absence of ripe oocytes, diameter of the oocytes and histological observations. The stages were classified as immature (stage I), immature and developing (Stage II), maturing (stages III and IV), ripe (stage V), spawning (stage VI) and spent (stage VII). No specimens of spent stage were observed. Macroscopic classification was similar to those used in ICES (Table 1). The gonad measurements have shown in Tables 2 and 3.

Ovary maturation stages: In the immature stage (I), the ovary was too small, thread-like and transparent so that sex determination was difficult. The mean diameter of oocytes was 0.05 mm. No histological section was prepared successfully for this stage. In the stage II (immature and developing), the ovary was small, thin, long with smooth surface and soft texture. It was cream in color and had oocytes that could not be observed by naked eye. The mean diameter of oocytes was 0.07 mm (Fig. 2a). In the histological observations (Fig. 3a-b), two oocyte

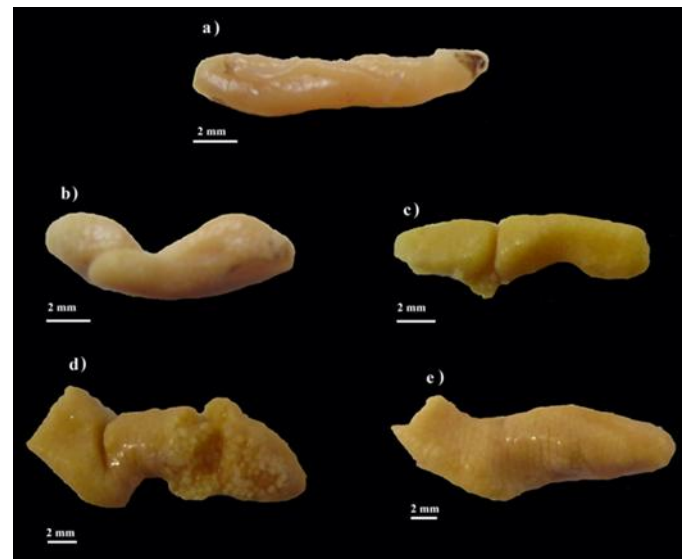


Figure 2. Morphological profiles of the female maturity stages of *P. waltoni*, Helleh estuary, southwestern Iran. (a) Immature and developing stage, (b, c) Maturing stages, (d) Ripe stage, and (e) Spawning stage.

types (I and II; mostly type II) with many interstitial tissue were observed. There was an extensive, light violet nucleus in the center of oocyte with abundant nucleolus around the nucleoplasm. In larger oocytes, the lipid droplets were formed in the cytoplasm and

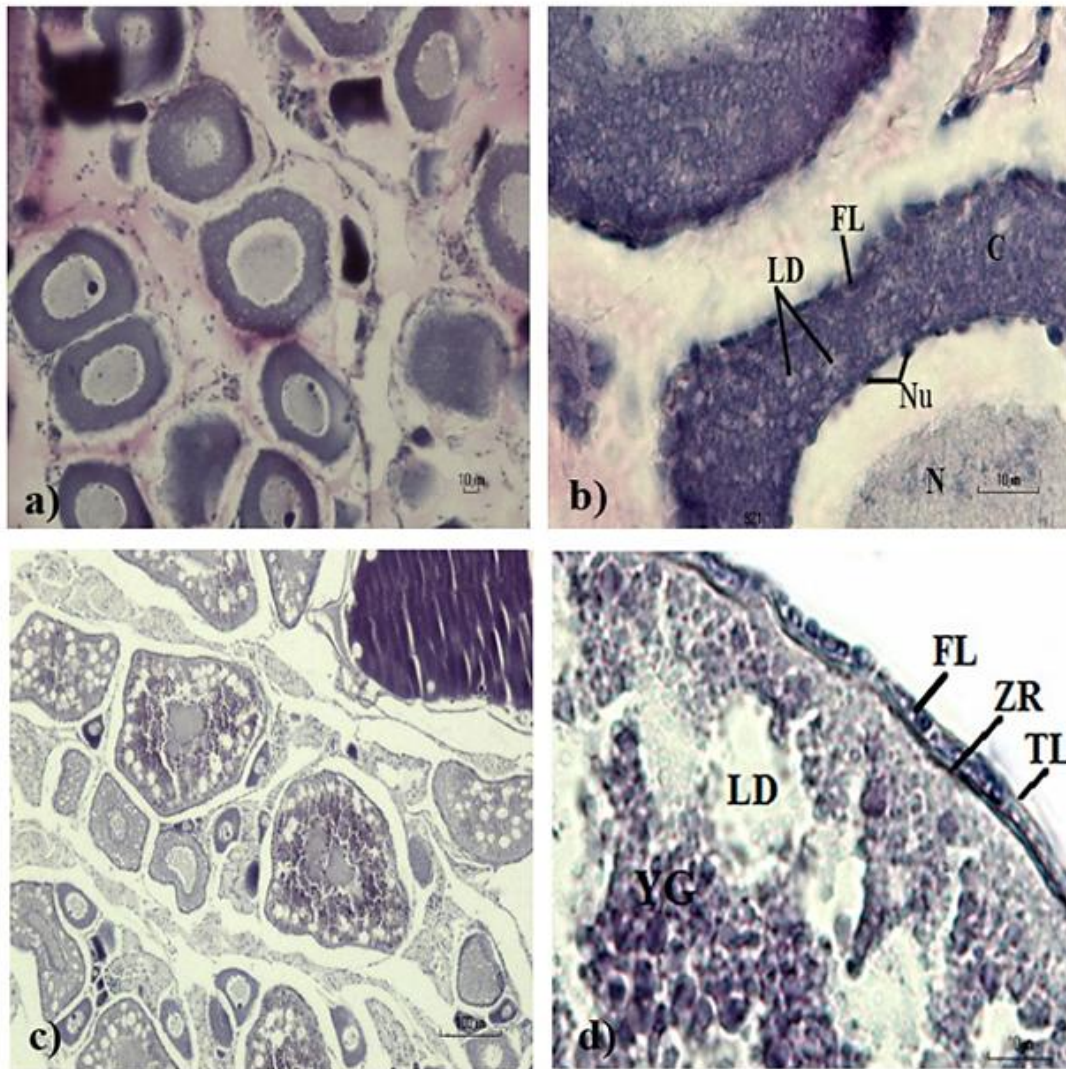


Figure 3. Histological profiles of the female maturity stages of *P. waltoni*, Helleh estuary, southwestern Iran. (a-b) Immature and developing stage, (c-d) Maturing stages N: Nucleou, Nu: Nucleolus, C: Cytoplasm, LD: Lipid Droplets, FL: Follicular Layer, YG: Yolk Granules, TL: Theca Layer, FL: Follicular Layer, ZR: Zona Radiata.

follicular layer encloses oocyte.

In the third stage (maturing), the size of ovary increased, it was lobulated and its color changed from cream to light yellow because of the accumulation of yolk materials. The oocytes were not visible by naked eye in this stage. The mean diameter of oocytes was 0.1 mm (Fig. 2b). The histological sections showed three oocyte types (I, II and III; mostly III) in the ovaries with developed interstitial tissues. Oocyte size was increased in this stage, the ratio of nucleus to cytoplasm was decreased; the lipid droplets increased and formation of yolk granules was distinguished. Furthermore, the follicular layer and zona radiata were appeared around the oolema (Fig. 3c-d). In the maturing stage

(IV), the ovary increased in size due to increasing of the yolk of the oocytes, its color changed to yellow, and wrinkled. The mean diameter of oocytes was 0.3 mm (Fig. 2c). In this stage, the oocytes are known as follicles. Their size were increased and the ratio of the nucleus to cytoplasm and interstitial tissue were decreased. In comparison to the lipid droplets, the yolk granule accumulations were significant. Zona radiata was thickened and follicular layer developed compared to previous stages. A thickening structure was found between the zona radiata and follicular layer, which could be the site of the micropyle (Fig. 4a-c). In the ripe stage (V), due to increasing the ovary size and abdominal cavity restriction a little folding was observed in gonad. Following the

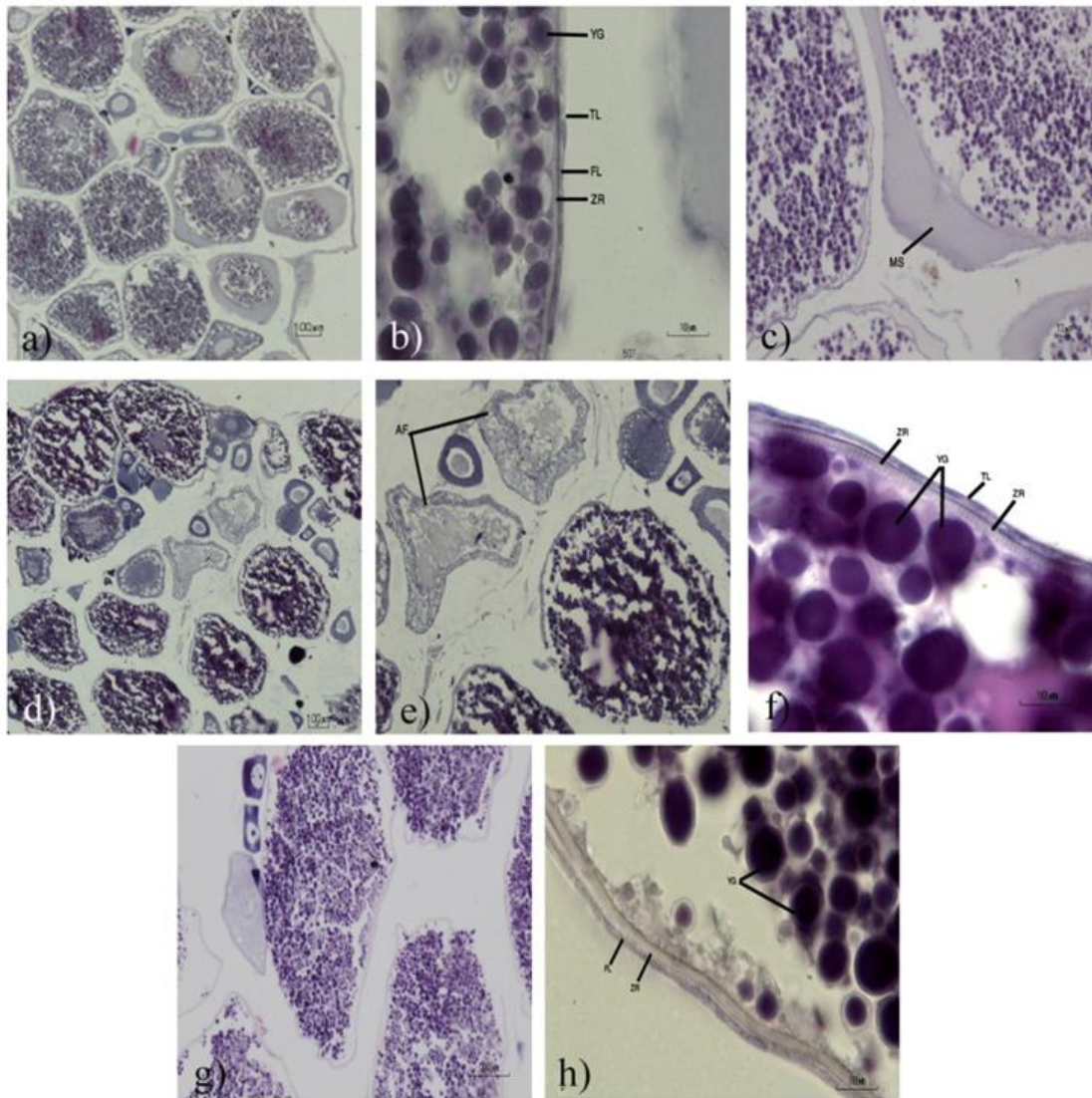


Figure 4. Histological profiles of the female maturity stages of *P. waltoni*, Helleh estuary, southwestern Iran. (a-c) Maturing stages, (d-f) Ripe stage, (g-h) Spawning stage LD: Lipid Droplets, FL: Follicular Layer, YG: Yolk Granules, TL: Theca Layer, FL: Follicular Layer, ZR: Zona Radiata.

reduction of ovary interstitial tissue, cohesion between oocytes was decreased. The mean diameter of oocytes was 0.46 mm in this stage (Fig. 2d). In microscopic observations, follicular sizes, density of yolk granules and thickness of zona radiata increased and the ratio of nucleus to cytoplasm decreased and some of the follicles were in absorbing stage. Follicular cells changed their shapes from cuboid to pavement state (Fig. 4d-f). In the spawning stage (VI), the ovary obtained its maximum size, having very thin epithelium with loosely oocytes connected to each other. The mean diameter of oocytes was 0.61 mm in this stage (Fig. 2e). In microscopic sections, the follicle sizes increased and almost no

nucleus was visible because of accumulation of yolk granules. In spawning stage, thickness of the zona radiata and theca layer was increased and decreased, respectively (Fig. 4g-h).

Testes maturation stages: The position of the testes was the same as ovary. Their weights, lengths and widths were increased during the gonadal developmental but not as large as ovary and their color was changing from grey to milky during gonadal development. The main histological characteristics which correspond to the maturation stages are the spermatogenesis process. In this study, five spermatogenic cells were diagnosed as follow: (I) Spermatogonia stage: They were the largest

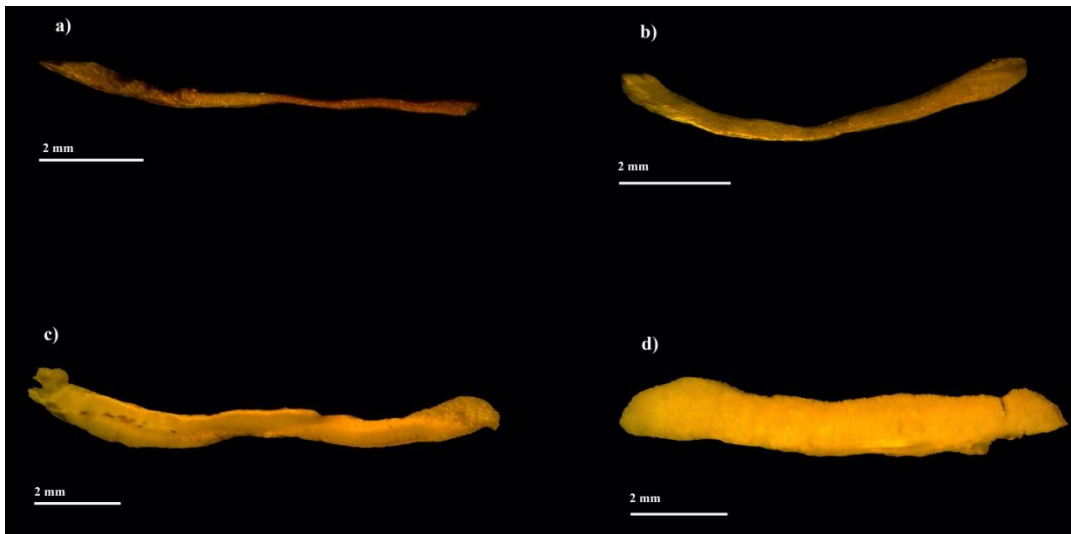


Figure 5. Morphological profiles of the male maturity stages of *P. waltoni*, Helleh estuary, southwestern Iran. (a) Immature stage, (b) Immature and Developing stage, (c) Maturing stage, and (d) Ripe stage.

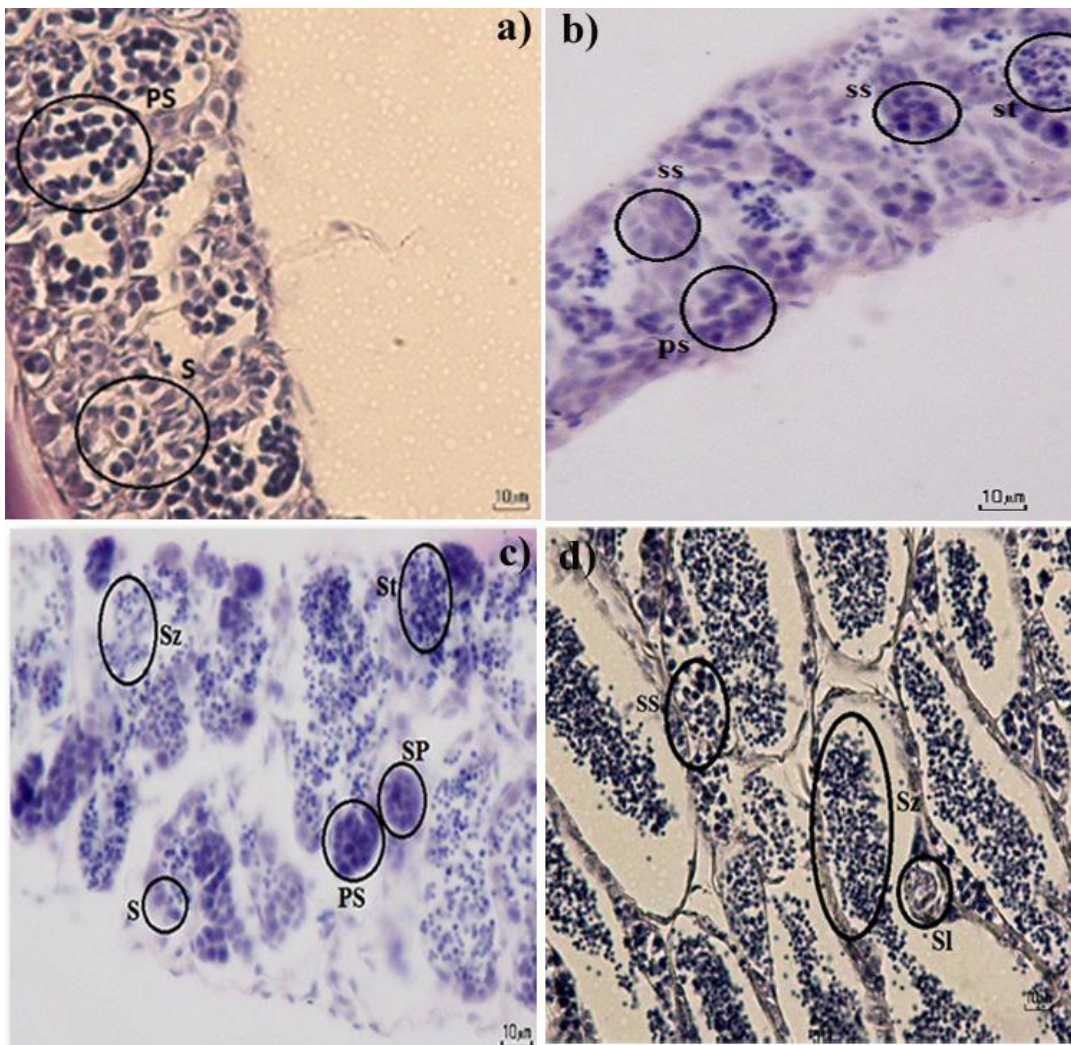


Figure 6. Histological profiles of the male maturity stages of *P. waltoni*, Helleh estuary, southwestern Iran. (a) Immature stage, (b) Immature and Developing stage, (c) Maturing stage, (d) Ripe stage S: Spermatogonia, PS: Primary Spermatocyte, SS: Secondary Spermatocyte, St: Spermatozoa, Sz: Spermatozoa, Sl: Sertoli cell

spermatogenic cell, with clear cytoplasm and large nucleus. The cysts or nests were absent. (II) Primary spermatocytes stage: These cells possess nuclei that were densely packed. (III) Secondary spermatocytes: They were similar to primary spermatocytes but smaller. (IV) Spermatids: They were smaller in size than secondary spermatocytes and possess dense nuclei. (V) Spermatozoa: The Spermatozoa were the smallest and densest spermatogenic cells and product of modifications of spermatid cells. They were concentrated in the seminal lobules after breaking through the nest wall.

The sperms, later acquired the ability to be mobile in the seminal fluid. This signifies the final product of the process of spermatogenesis. Macroscopically and microscopically, testes were classified into four developmental stages, including immature (stage I), immature and developing (stage II), maturing (stage III) and ripe (stage IV). Testes measurements are shown in Table 3.

In the immature stage (I), the testes were very small, thread like and grey (Fig. 5a). Spermatogonia and primary spermatocytes were differentiable in the histological sections (Fig. 6a). In the second stage (immature and developing), the sizes of whitish cream gonads were increased (Fig. 5b). In addition to previous stage, the histological sections showed the presence of the secondary spermatocytes and few accumulation of the spermatids (Fig. 6b). In the maturing stage (III), the testes were elongated, thickened and milky in colour (Fig. 5c). The number of the spermatogonia were reduced, a little spermatozoa were observed but spermatids were dominant (Fig. 6c). In the stage IV (ripe), the testes were more elongated, thickened and milky (Fig. 5d). In this stage, the gonads were ripe as milt released by cutting part of testis. In histological observations, nearly within all of the tubules were full of spermatozoa (Fig. 6d).

Discussion

Based on the results, six stages of the ovary development, including immature, immature and developing, maturing, ripe, spawning and spent were

observed in *P. waltoni*. Lawson (2010, 2011) classified testis and ovary of *Periophthalmus papilio* into seven stages. The general pattern of the histological development of the ovaries in *P. waltoni* conforms to that of the most teleosts (EL-Gharabawy, 1996; Assem, 2000, 2003). Teleost ovaries can be divided into three types based on the pattern of oocyte development viz. synchronous, group synchronous and asynchronous (Nagahama, 1983). In histological observations of *P. waltoni* ovaries, in each stage, the follicles were at different developmental stages, but at ripe and spawning stages, most of the follicles were developed. The simultaneous presence of three clearly distinct sizes of oocytes in ripe ovaries of *Gobius vittatus* (Gobiidae) indicated that this species is a multiple spawner (Kovacic, 2007).

Testicular structure in teleosts can be classified into two types i.e. tubular and lobular, depending on the pattern of spermatogenesis (Billard et al., 1982). The testis of *P. waltoni* is tubular that is the same as *Scartelaos gigas* (Kim et al., 2011). Development of sperm or milt in fish passes through multiplication, growth and maturation stages. The testis of *P. waltoni* is similar to other species consisting seminiferous tubules, spermatogonium, spermatocyte, spermatids and spermatozoon. Their presence was an indication that the gamete or sperm had gone through process of maturation (spermatogenesis) as were observed in Figures 5-6.

In the present study, there was variation in the monthly GSI values, The highest GSI values correspond to when the gonads were at ripe and ripe running stages (spawning phase), while the lowest GSI values indicate totally spent stage or starting developing stage (recovering stages). GSI of female was peaked in spring and autumn, and that of males were peaked in spring, but no peak was observed in autumn in male, maybe because of no enough collected male specimens in this season. The fish burrows in the mud flats that might be responsible for fewer collected specimens. The GSI for females was always higher than males. This has been reported in other fishes (Pajuelo and Lorenzo, 2000;

Esmaeili and Shiva, 2006). The mean of GSI was higher in female in reproduction season (Mahomoud et al., 2011). The GSI varied with species, sex, seasons and availability of food (see Pajuelo and Lorenzo, 2000; Esmaeili and Shiva, 2006; Mahomoud et al., 2011). This index has been widely used as indicator of the fish spawning season, but its use in reproductive biology studies is more suitable when it is associated with other reproduction indicators such as macroscopic and histological techniques. This is very important in males since differences in gonad size (length and weight) are less conspicuous than in females. Our findings demonstrated that spawning season of *P. waltoni* is in spring and autumn interpreted from the results of reproductive index (e.g. GSI) and gonad histology. Therefore, this study has provided information on the maturation process and reproductive cycle of mudskipper, *P. waltoni* in the coastal area of Persian Gulf which contribute baseline data towards management ecology, conservation and biological studies of this fish.

Acknowledgments

We are thankful to S. Babai, S. Mirghiasi and R. Zamaniannjad for their kind help in fish collection and Shiraz University for financial support.

References

- Assem S.S. (2000). The reproductive biology and histological characteristics of pelagic Carangid female *Caranx crysos*, from the Egyptian Mediterranean Sea. *Journal of the Egyptian German Society of Zoology*, 31(C): 195-215.
- Assem S.S. (2003). The reproductive biology and histological and ultrastructural characteristics of the ovary female pelagic fish *Pagellus erythrinus* from the Egyptian Mediterranean water. *Journal of the Egyptian German Society of Zoology*, 42: 77-103.
- Billard R., Fostier A., Weil C., Breton B. (1982). Endocrine control of spermatogenesis in teleost fish. *Canadian Journal of Fisheries and Aquatic Sciences*, 39: 65-79.
- Clayton D.A. (1993). Mudskippers. *Oceanography and Marine Biology: An Annual Review*, 31: 507-577.
- El-Gharabawy M.M. (1996). Histomorphology of ovarian changes during the reproductive cycle of *Lithognathus mormyrus* (Teleoste: Sparidae). *Journal of the Egyptian German Society of Zoology*, 19(A): 97-115.
- Eschmeyer W.N., Fong H.D. (2015). *Catalog of Fishes*. Available from: <http://researcharchive.calacademy.org/research/ichthyology/catalog/fishcatmain.asp>.
- Esmaeili H.R., Coad B.W., Gholamifard A., Nazari N., Teimory A. (2010). Annotated checklist of the freshwater fishes of Iran. *Zoosystematica Rossica*, 19(2): 361-386.
- Esmaeili H.R., Shiva A.H. (2006). Reproductive biology of Persian tooth- carp, *Aphanius persicus* (Jenkins, 1910) (Actinopterygii: Cyprinodontidae) in South of Iran. *Zoology in the Middle East*, 37: 39-46.
- Ghanbarifardi M., Malek M. (2007). Permanent intertidal fish from the Persian Gulf and Gulf of Oman, Iran. *Iranian Journal of Animal Biosystematics* 3(1): 1-14.
- Ghanbarifardi M., Aliabadian M., Esmaeili H.R. (2014a). Morphometric variation of *Periophthalmus waltoni* Koumans, 1941 (Teleostei: Gobiidae) in the Persian Gulf and Gulf of Oman. *Iranian Journal of Animal Biosystematics*, 10(2): 137-144.
- Ghanbarifardi M., Aliabadian M., Esmaeili H.R., Polgar G. (2014b). Morphological divergence in the Walton's mudskipper, *Periophthalmus waltoni* Koumans, 1941, from the Persian Gulf and Gulf of Oman (Gobioidae: Gobiidae). *Zoology in the Middle East*, 60(2): 133-143.
- Gordon M.S., Boetius I., Evans D.H., McCarthy R., Oglesby L.C. (1969). Aspects of the physiology of terrestrial life in amphibious fishes I: the mudskipper, *Periophthalmus sobrinus*. *Journal of Experimental Biology*, 50: 141-149.
- Graham J.B. (1997). Air-breathing fishes. Evolution, diversity and adaptation. San Diego California. Academic Press, 65-133
- Harris V.A. (1960). On the locomotion of the mudskipper *Periophthalmus koelreuteri* (Pallas). Gobiidae. *Proceedings of the Zoological Society of London*, 134: 107-135.
- ICES (1963). Recommendations adopted by the Herring committee concerning routine methods and the reporting of herring biological data in the ICES' area. *Proces-verbal de la Reunion*. Appendix 1, pp: 71-73.
- ICES. (1999). *Manual for international bottom trawl*

- surveys. ICES CM. D2, Addendum 2.
- Kim J.K., Baek H., Kim J., Chang D., Kim J. (2011). Sexual maturity and early life history of the mudskipper *Scartelaos gigas* (Pisces, Gobiidae), implications for conservation. *Fisheries and Aquatic Sciences*, 14(4): 403-410.
- Kovacic M. (2007). Reproductive biology of the striped goby, *Gobius vittatus* (Gobiidae) in the northern Adriatic Sea. *Scientia Marina*, 71(1): 145-151.
- Lawson E.O. (2010). Maturation and Histological characteristics of ovaries in Mudskipper, *Periophthalmus papilio* from Lagos lagoon, Nigeria. *Journal of American Science*, 6(11).
- Lawson E.O. (2011). Testicular maturation and reproductive cycle in mudskipper, *Periophthalmus papilio* (Bloch and Schneider 1801) from Lagos lagoon, Nigeria. *Journal of American Science*, 7(1).
- Lee H.J., Graham J.B. (2002). Their game is mud. *Natural History*, 9(2): 42-47.
- Murdy E.O. (1989). A Taxonomic Revision and Cladistic Analysis of the Oxudercine Gobies (Gobiidae: Oxudercinae). *Records of the Australian Museum, Supplement*, 11: 1-93.
- Nagahama Y. (1983). The functional morphology of teleost gonads. In: W.S. Hoar, D.J. Randall, E.M. Donaldson (Eds.). *Fish Physiology*. San Diego, California, USA, Academic Press. pp: 223-275
- Pajuelo J.G., Lorenzo J.M. (2000). Reproduction, age, growth and mortality of axillary seabream, *Pagellus acarne* (Sparidae) from the Canarian archipelago. *Journal of Applied Ichthyology*, 16(2): 41-47.
- Polgar G. (2008). Species-area relationship and potential role as a biomonitor of mangrove communities of Malayan mudskippers. *Wetlands Ecology and Management*, 17: 157-164.
- Swanson B.O., Gibb A.C. (2004). Kinematics of aquatic and terrestrial escape responses in mudskippers. *The Journal of Experimental Biology*, 207: 4037-4044.
- Thacker C.E. (2003). Molecular phylogeny of the gobioid fishes (Teleostei: Perciformes: Gobiioidei). *Molecular Phylogenetics and Evolution*, 26: 354-368.
- Thacker C.E. (2009). Phylogeny of Gobiodei and placement within Acanthomorpha, with a new classification and investigation of diversification and character evolution. *Copeia*, 93-104.
- Thacker C.E. (2013). Phylogenetic placement of the European sand gobies in Gobionellidae and characterization of gobionellid lineages (Gobiiformes: Gobiioidei). *Zootaxa*, 3619(3): 369-382.
- Wong L.C., Corlett R., Young L., Lee J.Y. (2000). Comparative feeding ecology of little egrets on intertidal mudflats in Hong Kong, South China. *Water Birds*, 23: 214-225.

چکیده فارسی

ویژگی‌های ریختی و بافت‌شناسی گنادهای ماهی گل خورک *Periophthalmus waltoni* Koumans, 1941 از مصب هله، جنوب غربی ایران

سمیه قاسمیان^۱، حمیدرضا اسماعیلی^{۱*}، محسن نخبه الفقهای^۱، عبدالرحیم پذیرا^۲
^۱گروه زیست‌شناسی، دانشکده علوم، دانشگاه شیراز، شیراز، ایران.
^۲گروه شیلات، دانشگاه آزاد اسلامی، واحد بوشهر، بوشهر، ایران.

چکیده:

این تحقیق، به منظور تعیین مراحل بلوغ جنسی، مطالعه ریخت و بافت‌شناسی (ماکروسکوپی و میکروسکوپی) گنادهای جنس‌های نر و ماده ماهی گل خورک، *Periophthalmus waltoni* Koumans, 1941 از مصب هله در استان بوشهر، جنوب ایران صورت گرفت. نمونه‌برداری از ماه آوریل ۲۰۱۰ تا مارس ۲۰۱۱ صورت گرفت و در مجموع تعداد ۸۱ نمونه به وسیله ساچوک دستی، جمع‌آوری گردید. گنادهای نمونه‌های ماهی از بدن خارج شدند، جنسیت آنها تعیین گردید و بعد از بررسی ریختی، اندازه‌گیری وزن، طول و عرض آنها، در محلول فرمالین ۱۰٪ تثبیت شدند. به کمک مشاهدات ماکروسکوپی و میکروسکوپی و بررسی شاخص تولیدمثلی، ۶ مرحله بلوغ جنسی برای ماده‌ها و ۴ مرحله برای نرها تعیین گردید. در گنادهای ماده، به دلیل افزایش تجمع مواد زرده‌ای در اووسیت‌ها، اندازه تخمک افزایش یافته بود، و در مراحل آخر به دلیل محدودیت حفره شکمی در طی توسعه گناد، کمی چین خوردگی در تخمدان مشاهده شد. تشکیل لایه شعاعی شفاف و گرانول‌های زرده‌ای در مرحله سوم و افزایش ضخامت این لایه و گرانول‌های زرده‌ای از مرحله سوم تا ششم قابل مشاهده بودند. در گنادهای نر، توسعه تدریجی سلول‌های اسپرم از مرحله اول قابل مشاهده بود.

کلمات کلیدی: Gobiidae، شاخص‌های تولیدمثلی، بافت‌شناسی گناد، ایران.