



Original Article

Histoarchitectural and surface ultrastructural analysis of the olfactory epithelium of *Puntius ticto* (Hamilton, 1822)

Saroj Kumar Ghosh^{*1,2}, Bappaditya Pan³, Padmanabha Chakrabarti²

¹Department of Zoology, Bejoy Narayan Mahavidyalaya, Itachuna, Hooghly-712147, West Bengal, India.

²Fisheries Laboratory, Department of Zoology, The University of Burdwan, Burdwan-713104, West Bengal, India.

³University Science Instrumentation Centre, The University of Burdwan, Burdwan-713104, West Bengal, India.

Abstract: Organization of various cells lining the olfactory mucosa of *Puntius ticto* (Hamilton, 1822) were described by light as well as scanning electron microscopy. The paired olfactory chambers located antero-dorsal to the eyes and communicated outside through anterior and posterior nasal openings. The oval shaped olfactory rosette lied at the bottom of chamber and composed of 18-20 lamellae arranged on either side of median raphe. Sensory and non-sensory regions were distributed separately on each lamella. The sensory epithelium consisted mainly of two distinct morphological forms: ciliated and microvillous receptor cells. The non-sensory epithelium contained ciliated non-sensory cells, stratified epithelial cells with concentric microridges and mucous cells. Basal cells were situated at the deeper part of the epithelium, adjacent to the central core. The functional significance of cellular components of the olfactory epithelium was discussed with the habit and habitat of fish.

Article history:

Received 10 April 2015

Accepted 7 July 2015

Available online 25 August 2015

Keywords:

Olfactory organ

Functional anatomy

Histology

Scanning electron microscopy

Introduction

Olfaction is one of the most important senses driving basic patterns of behavior in fishes and involved in food searching, nest finding, predator-prey relationship, mother-infant recognition, kin identification, reproductive behavior, homing behavior and in many other ways (Farbman, 1994). Functional neuroanatomy of olfactory apparatus is attracting to study as it is the only organ in teleost where receptor neurons are directly exposed to aquatic environment. The receptor cells lining the olfactory epithelium are stimulated when they come into contact with water containing chemicals pass from nostrils to the olfactory mucosa and transmit signals to the nervous system (Lara, 2008). The olfactory organs of fish exhibits extensive array of diversification relying upon systematic groups, life styles and ecological adaptations (Zeiske et al., 2009). Extensive investigations and information on

the microarchitecture of the olfactory epithelium of different teleosts are well-documented using light and electron microscope (Zeiske et al., 1994; Byrd and Brunjes, 1995; Diaz et al., 2002; Hansen and Zielinski, 2005; Lazzari et al., 2007; Chakrabarti and Ghosh, 2009; 2011; Atta, 2013; Ghosh and Chakrabarti, 2014). Still lacunae exist in some aspects of the studies relating to the cellular basis of olfaction among cyprinids.

The present study attempts at finding out the detailed functional organization of the olfactory system in freshwater ticto barb, *Puntius ticto* (Cypriniformes, Cyprinidae), found mostly at surface layer of waters and feeds on crustaceans, insects, planktons etc. (Banik and Saha, 2012).

Materials and Methods

Tissue collection: A total of 24 adult live specimens of *P. ticto* (ranged 5.84 ± 0.06 cm in total length)

* Corresponding author: Saroj Kumar Ghosh
E-mail address: saroj.fisherylab@gmail.com

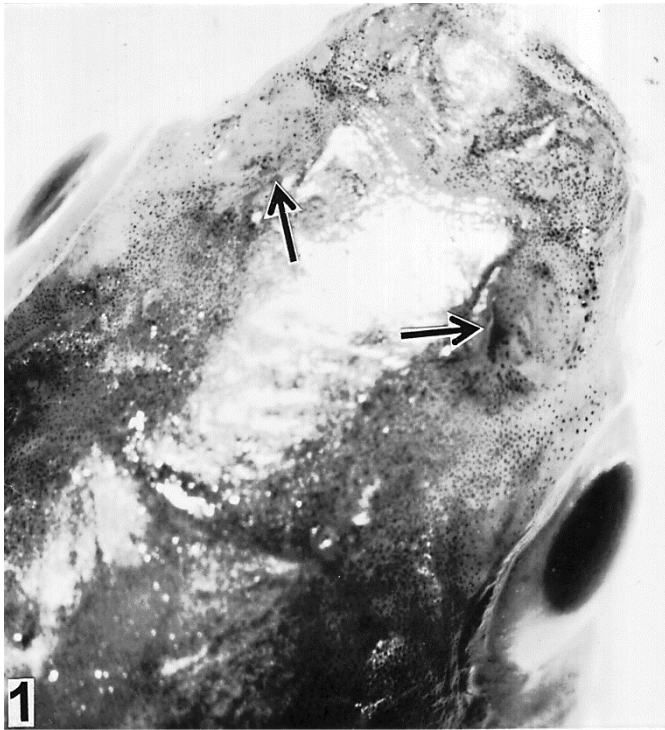

Figure 1. Dorsal view of head of *P. ticto* showing the position of olfactory pits (arrows).

were procured from regional freshwater pond of Burdwan (23.2333°N, 87.8667°E), West Bengal, India during September-December, 2014. Fish were anesthetized with an aqueous solution of benzocaine (4 mg L⁻¹) and sacrificed following the guidelines given by the Institutional Ethical Committee. Intact olfactory organs were attentively dissected out from the olfactory chamber under a Zeiss Stemi 2000-C stereoscopic binocular microscope and further processed for respective studies.

Histological preparation: The olfactory tissues were immediately fixed in aqueous Bouin's fixative for 16-18 hrs. After that, the fixed tissues were washed thoroughly in 70% ethanol, dehydrated with graded series of ethanol and cleared in xylene. Then, the tissues were infiltrated in paraffin wax of 56-58°C under a thermostat vacuum paraffin-embedding bath for one hrs. Serial paraffin sections were cut at 4 µm thickness using Leica RM 2125 RT microtome. After routine histological process deparaffinized sections were stained with Delafield's Haematoxylin-Eosin (HE) and Mallory's Triple (MT) stain (Mallory, 1936) and observed under an Olympus-Tokyo PM-6 compound microscope.

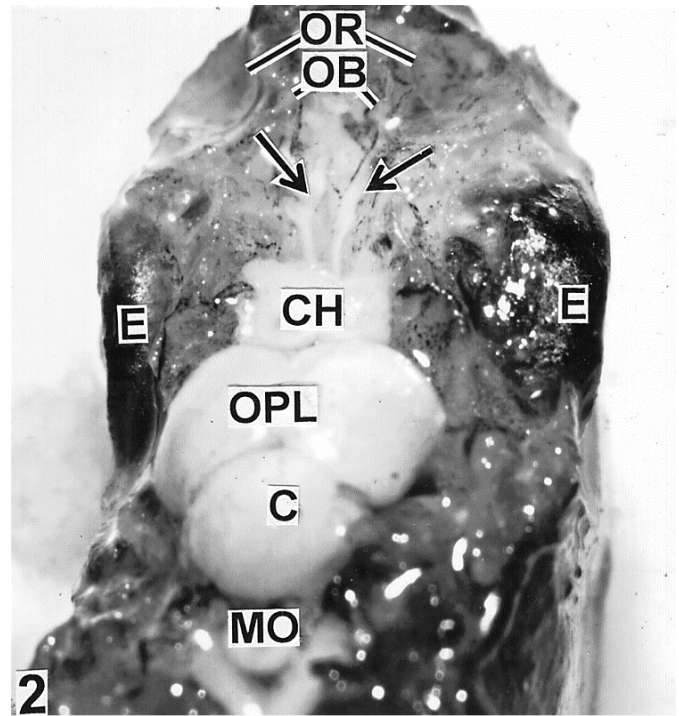


Figure 2. Dissection of head from the dorsal side showing the anatomical relationship of the brain and the olfactory rosettes (OR) along with olfactory nerves (arrows) and olfactory bulbs (OB). CH represents cerebral hemisphere; OPL: optic lobe; C: cerebellum; MO: medulla oblongata.

Scanning electron microscopical (SEM) preparation:

After dissecting the olfactory chamber the olfactory rosettes were immersed in vivo with 2.5% glutaraldehyde solution in 0.1 M phosphate buffer (pH 7.4) for 20 mins. Then, the olfactory rosettes were carefully dissected out and rinsed in 0.1 M phosphate buffer (pH 7.4). The samples were fixed with 2.5% glutaraldehyde for 24 hrs at 4°C and post fixed with 1% osmium tetroxide in 0.1 M phosphate buffer (pH 7.4) for two hrs. Fixed tissues were washed repeatedly in same buffer and dehydrated in ascending series of acetone followed by isoamyl acetate. The tissues were dried with critical point drier (Hitachi 8CP2), mounted on metal stubs, coated with gold palladium (20 nm thickness) and observed under a scanning electron microscope, Hitachi S-530.

Results

Puntius ticto bears a pair of the nasal pits located on the antero-dorsal surface of the head and slightly above the level of the eyes (Fig. 1). Each olfactory

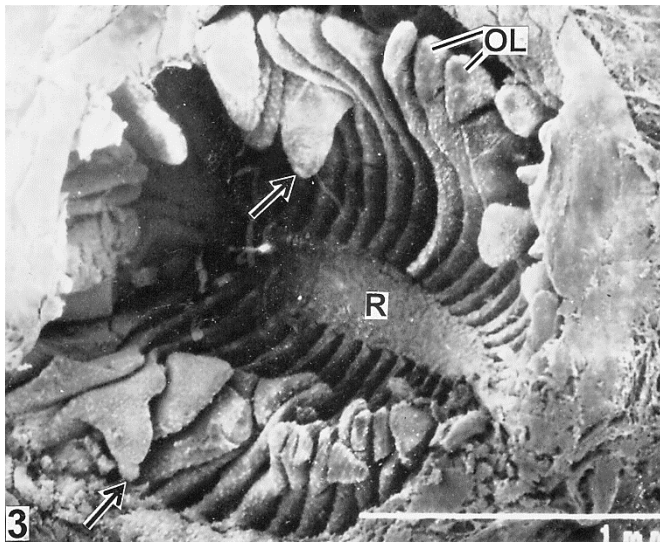


Figure 3. Oval shaped olfactory rosette supported with olfactory lamellae (OL) radiating from median raphe (R). Arrows mark linguiform processes of OL (SEM 60X).




Figure 4. Linguiform process of olfactory lamellae (OL) showing sensory epithelium covered with dense aggregation of receptor cells (RC) (SEM 600X).

chamber is occupied by an olfactory rosette and communicates outside by two openings which lie close to each other. The olfactory chamber along with olfactory rosette is resided in a fossa framed in the ethmoid region of the skull and is affixed to the neighboring bones by connective tissues. Olfactory rosettes along with olfactory bulbs are connected to the telencephalon by narrow olfactory nerves (Fig. 2).

The olfactory rosette is an oval texture with a convex ventral and a concave dorsal surface, occupying the entire space in the olfactory chamber (Fig. 3). The

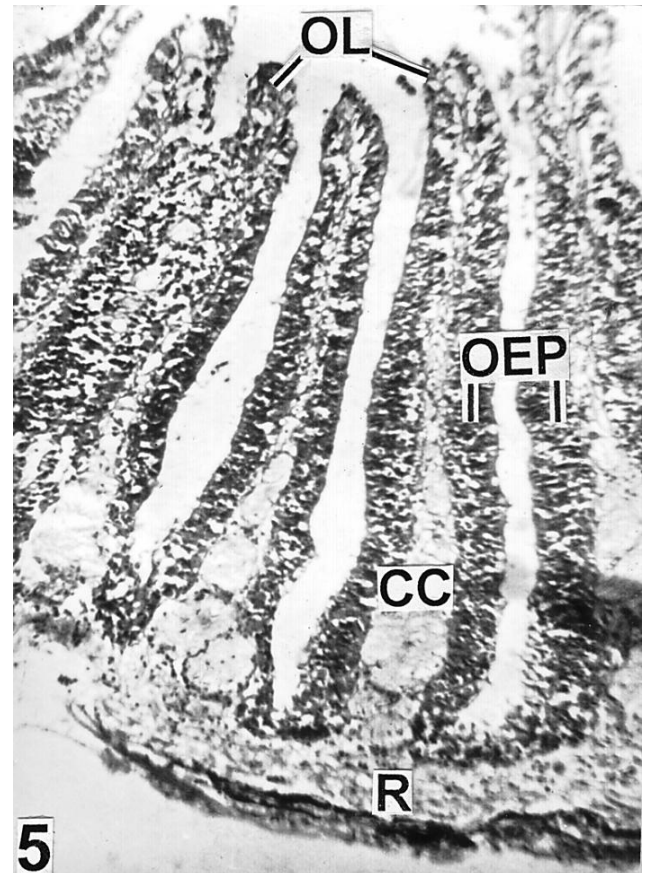


Figure 5. Olfactory lamellae (OL) based on raphe (R) showing organized olfactory epithelium (OEP) separated by the central core (CC) (HE 150X).

rosette holds a central median raphe which is framed with 18-20 bilaterally arranged olfactory lamellae. The lamellae are closely set and conjoined to the wall of the olfactory chamber by their convex inner edges where as to the raphe by their proximal ends. The magnitude of lamellae differs in relation to their position in rosette. The lamellae are large in the middle and reduce in size towards anterior and posterior ends of the olfactory rosette (Fig. 3). The anterior and posterior lamellae are adhered obliquely to the raphe while the middle portions are nearly perpendicular. Olfactory lamellae are distinguished into sensory and non-sensory epithelium. The outer concave margins of the lamellae bear well-developed linguiform processes (Fig. 3) covered with sensory epithelium (Fig. 4), whereas resting part of the lamellae are characterized with non-sensory epithelium.

Histologically each olfactory lamella consists of the olfactory epithelium and a central lamellar space,

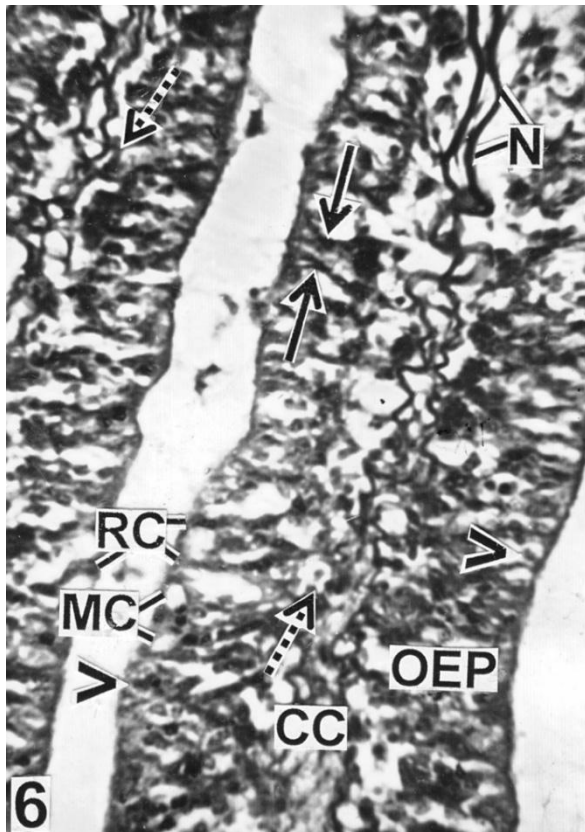


Figure 6. Olfactory epithelium (OEP) showing the arrangement of prominent receptor cells (RC), stratified epithelial cells (arrow heads), mucous cells (MC) and basal cells (broken arrows) adjacent to central core (CC). Solid arrows indicate bipolar dendrites of RC. Note prominent nerve fibers (N) in CC (MT 600X).

the central core (Fig. 5). The central core is composed of the loosely connective tissue containing nerve fibers (Figs. 6, 7) and blood vessels. The olfactory epithelium is made up of the compactly arranged receptor cells having long dendrite reaching up to the free epithelial surface. In between the receptor cells, the mucous cells and stratified epithelial cells are present (Fig. 6). The sensory epithelium is composed of a primary, secondary and few microvillous receptor cells. The primary receptor cells have long dendrite processes reaching up to the free epithelial surface and cell bodies with rounded, deeply stained nuclei located deep in the epithelium (Fig. 7). The secondary receptor cells are differentiated by their elongated oval nuclei, present below the primary receptor cells and extend up to the central core below. Microvillous receptor cells are small in number, more superficial

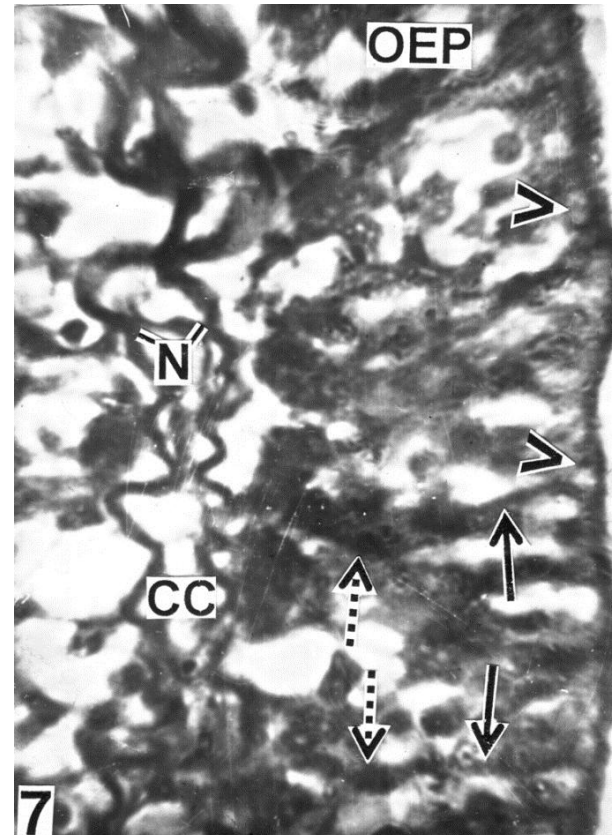


Figure 7. Higher magnification of sensory olfactory epithelium (OEP) showing primary (solid arrows), secondary (broken arrows) and microvillous (arrow heads) receptor cells. Note the presence of nerve fibers (N) in central core (CC) (HE 1000X).

in the olfactory epithelium having lightly stained nuclei but without cilia (Fig.7). In some areas of the olfactory epithelium, the receptor cells are characterized with bipolar dendrites (Fig. 6). Scanning electron microscopic investigations have shown that the sensory epithelium consists of the morphologically distinct two types of receptor cells: ciliated and microvillous (Fig. 8). Ciliated receptor cells are provided with cluster of long cilia, rise above the epithelial surface. On contrary, microvillous receptor cells contain short dendrons and exhibits carving texture. Ciliated receptor cells are the dominant over microvillous receptor cells. Non-sensory epithelium is comprised of patches of ciliated non-sensory cells and polygonal stratified epithelial cells with irregularly arranged microridges showing finger print like architecture (Fig. 9). Secreted mucins from mucous cells are present over the microridges of the stratified epithelial cells.

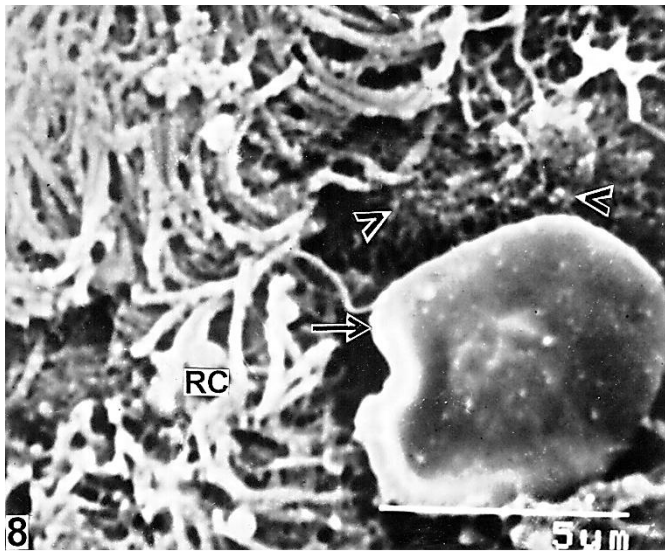


Figure 8. Surface view of sensory epithelium showing microvillous receptor cells (arrow heads) circumscribed by cluster of ciliated receptor cells (RC). Solid arrow indicates blood cell (SEM 5000X).

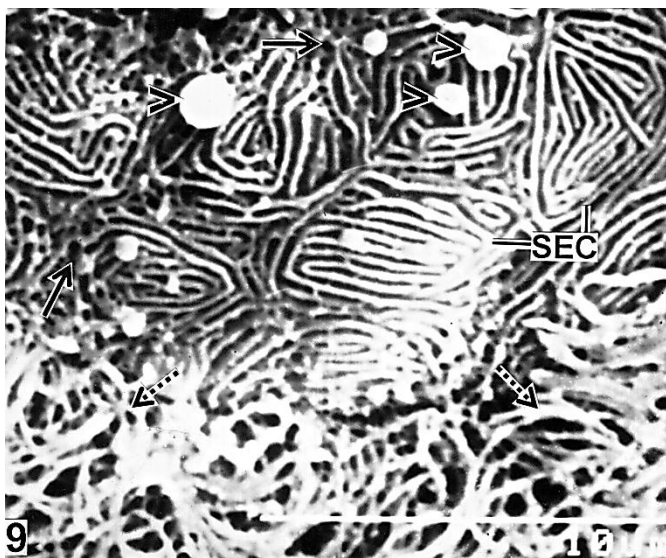


Figure 9. Surface architecture of non-sensory epithelium showing patchy distribution of ciliated non-sensory cells (broken arrows) and polygonal stratified epithelial cells (SEC) with fingerprint like microridges. Note the presence of scattered mucous cells (solid arrows) and retention of mucin droplets (arrow heads) over SEC (SEM 4500X).

Under optical microscope, the non-sensory epithelium is mainly lined with stratified epithelial cells having prominent nuclei and scattered mucous cells (Fig. 10). Basal cells are almost round in shape having centrally placed prominent nuclei and chromophobic cytoplasm, located in the deeper part of the epithelium (Figs. 6, 10). The surface epithelium of raphe is marked by compactly

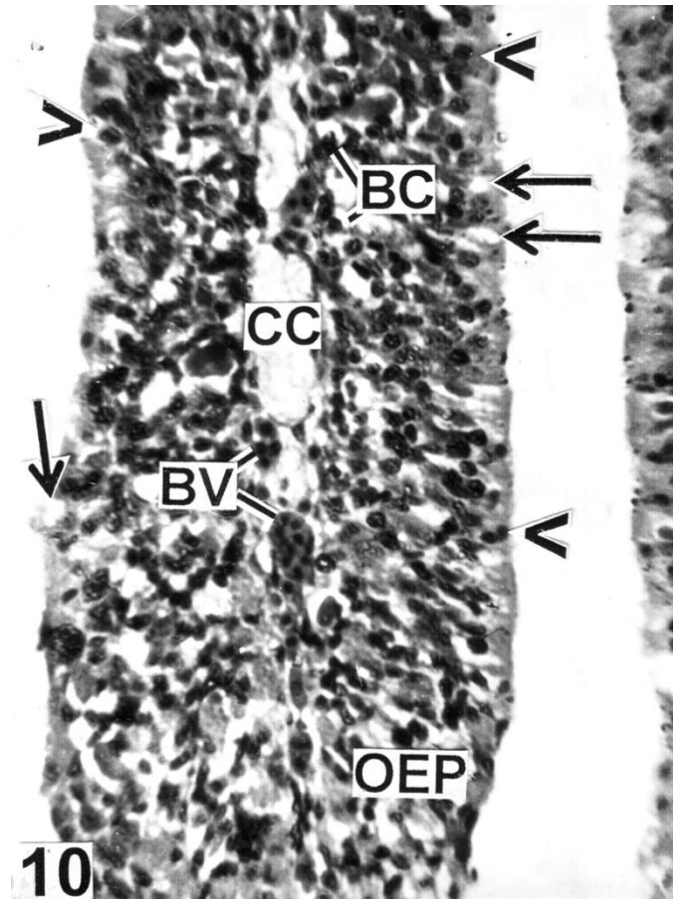


Figure 10. Non-sensory epithelium (OEP) lined with stratified epithelial cells (arrow heads) and mucous cells (solid arrows). Note the presence of basal cells (BC) near the central core (CC) provided with blood vessels (BV) (MT 600X).

arranged stratified epithelial cells with concentric microridges interspersed with mucous cells (Fig. 11).

Discussion

Olfactory organ of fish is essentially a chemoreceptor and plays a meaningful role not only locating food but also detecting the presence of odoriferous substances in the aquatic ecosystem (Datta and Das, 1980). Fish possesses a good sense of smell and are able to detect odour with the help of a pair of olfactory rosettes connected to the olfactory lobes of the brain by means of olfactory tracts (Singh, 1977). In *P. ticto*, the olfactory rosettes are paired, located at the bottom of olfactory chamber which contain two openings through which water enters and leaves. During forward progression of fish the unidirectional circulation of water containing



Figure 11. Surface feature of raphe characterized with stratified epithelial cells (SEC) having concentric microridges. Note the presence of mucous cells (solid arrows) and mucin mass (arrow heads) over SEC (SEM 5500X).

odorants through the olfactory chamber is brought about by the activity of cilia present in the anterior nasal opening and the olfactory epithelium (Goel, 1978).

The oval shaped rosette of *P. ticto*, with 18-20 lamellae arranged on either side of the central median raphe, can be classified with Bateson's (1889) rosette type 3 or under Burne's (1909) rosette column I. The feeding habits of fish are reflected on the structural organization and size of sense organs particularly eye and olfactory apparatus (Atta, 2013). *Puntius ticto* possess equally developed vision and olfaction is thus a mediosmatic species and belongs to Teichmann's (1954) 1st group "eye-nose fishes". Olfactory rosette in *P. ticto* is multi lamellar, which increase the surface area of epithelium as well as the sensitivities and efficacy of the olfactory organ (Zeiske et al., 1976). The dorsal edges of the lamellae bear particularly well-developed linguiform processes which slow down the water flow over the olfactory mucosa and facilitate better interaction of odorants particles with receptor cells.

Sensory and non-sensory olfactory epithelium exhibits variation in distribution among teleosts

(Yamamoto, 1982). In *P. ticto*, sensory regions are confined mainly in the linguiform processes while non-sensory regions are scattered rest of the lamellae. Sensory epithelium consists of different type receptor cells whereas the non-sensory epithelium is made up of stratified epithelial cells and mucous cells. Ciliated receptor cells are known as generalists; respond to varying species of odorants including amino acids, bile salts and other chemical cues while microvillous cells are called as specialist, which respond specifically to amino acids and nucleotides (Hansen et al., 2003). The dendrite process of receptor cell which terminates at the free surface of the epithelium is the locus where olfactory transduction is initiated by contact with odoriferous substances (Reese, 1965). In the present study, bipolar neurons with cylindrical process have a special interest because they probably form a different olfactory transduction mechanism stimulated by odour bearing substances.

The surface of non-sensory epithelium is covered with a dense mat of non-sensory cilia which propel streams of incoming water and/or dissolved chemicals between the lamellae and the cilia of receptor cells (Singh and Singh, 1989). In *P. ticto*, the non-sensory epithelium is lined with principally of stratified epithelial cells characterized with finger print like microridges are thought to perform a role in supporting tissues exposed to abrasive forces (Uehara et al., 1991). The stratified epithelial cells have been suggested to perform several functions: secretory, absorbing and glial (Theisen, 1972; Yamamoto and Ueda, 1978; Hernadi, 1993; Hansen and Zeiske, 1998). Mucous cells secrete mucin which holds by the microridges of stratified epithelial cells, protects the olfactory epithelium from external hazards and lubricates the epithelial surface to smooth flow of water during ventilation. The mucus layer may also serve as an ion trap, which delays the access of heavy metals and salts to underlying organs (Waryani et al., 2013).

The basal cells are situated adjacent to the central core in both sensory and non-sensory olfactory epithelium of *P. ticto*, assumed to be the progenitor

cells of the receptor (Graziadei and Metcalf, 1971) and supporting cells (Ojha and Kapoor, 1973). Zeiske et al. (1992) reported that the basal cells can function as stem cells for regeneration of lost or damaged non-sensory and mucous cells.

Acknowledgments

The authors are grateful to Dr. S. Ray, Head of the Department of Zoology, The University of Burdwan, Burdwan for providing essential laboratory facilities.

References

- Atta K.I. (2013). Morphological, anatomical and histological studies on the olfactory organs and eyes of teleost fish: *Anguilla anguilla* in relation to its feeding habits. The Journal of Basic and Applied Zoology, 66: 101-108.
- Banik S., Saha S. (2012). *Puntius ticto* (Hamilton, 1822) of Tripura, India: reproductive physiology and biology. Journal of Environment, 1: 136-141.
- Bateson W. (1889). The sense-organs and perceptions of fishes; with remarks on the supply of bait. Journal of the Marine Biological Association of the United Kingdom, 1: 225-256.
- Burne R.H. (1909). The anatomy of the olfactory organ of teleostean fishes. Proceedings of Zoological Society of London, 2: 610-663.
- Byrd C.A., Brunjes P.C. (1995). Organization of the olfactory system in the adult zebrafish: histological, immunohistochemical, and quantitative analysis. The Journal of Comparative Neurology, 358: 247-259.
- Chakrabarti P., Ghosh S.K. (2009). Ultrastructural organisation and functional aspects of the olfactory epithelium of *Wallago attu* (Bleeker). Folia Morphologica, 68: 40-44.
- Chakrabarti P., Ghosh S.K. (2011). The structural organization and functional aspects of the olfactory epithelium of tigerperch, *Terapon jarbua* (Forsskål, 1775) (Perciformes: Terapontidae). Turkish Journal of Zoology, 35: 793-799.
- Datta N.C., Das A. (1980). Anatomy of the olfactory apparatus of some Indian gobioids (Pisces: Perciformes). Zoologischer Anzeiger, 3: 241-252.
- Diaz J.P., Prié-Granié M., Blasco C., Noël T., Connes R. (2002). Ultrastructural study of the olfactory organ in adult and developing European sea bass, *Dicentrarchus labrax*. Canadian Journal of Zoology, 80: 1610-1622.
- Farbman A.I. (1994). The cellular basis of olfaction. Endeavour, 18: 2-8.
- Ghosh S.K., Chakrabarti P. (2014). Structural characterization of the olfactory epithelium of freshwater olive barb, *Puntius sarana* (Hamilton, 1822). International Journal of Aquatic Biology, 2: 147-154.
- Goel H.R. (1978). The structure and functions of the olfactory organs in the freshwater teleost *Notopterus notopterus* (Ham.). Folia Morphologica, 26: 392-397.
- Graziadei P.P.C., Metcalf J.F. (1971). Autoradiographic and ultrastructural observations on the frog's olfactory mucosa. Zeitschrift für Zellforschung, 116: 305-318.
- Hansen A., Zeiske E. (1998). The peripheral olfactory organ of the zebrafish, *Danio rerio*: an ultra-structural study. Chemical Senses, 23: 39-48.
- Hansen A., Zielinski B.S. (2005). Diversity in the olfactory epithelium of bony fishes: development, lamellar arrangement, sensory neuron cell types and transduction components. Journal of Neurocytology, 34: 183-208.
- Hansen A., Rolen S.H., Anderson K., Morita Y., Caprio J., Finger T.E. (2003) Correlation between olfactory receptor cell type and function in the channel catfish. The Journal of Neuroscience, 23: 9328-9339.
- Hernadi L. (1993). Fine structural characterization of the olfactory epithelium and its response to divalent cations Cd²⁺ in the fish *Alburnus alburnus* (Teleostei, Cyprinidae): a scanning and transmission electron microscopic study. Neurobiology, 1: 11-31.
- Lara M.R. (2008). Development of the nasal olfactory organs in the larvae, settlement-stages and some adults of 14 species of Caribbean reef fishes (Labridae, Scaridae, Pomacentridae). Marine Biology, 154: 51-64.
- Lazzari M., Bettini S., Ciani F., Franceschini V. (2007). Light and transmission electron microscopy study of the peripheral olfactory organ of the guppy, *Poecilia reticulata* (Teleostei, Poeciliidae). Microscopy Research and Technique, 70: 782-789.
- Mallory F.B. (1936). The aniline blue collagen stain. Stain Technology, 11: 101.
- Ojha P.P., Kapoor A.S. (1973). Structure and function of the olfactory apparatus in the freshwater carp, *Labeo rohita* Ham. Buch. Journal of Morphology, 140: 77-85.
- Reese J.S. (1965). Olfactory cilia in the frog. Journal of

Cell Biology, 25: 209-230.

- Singh S.P. (1977). Functional anatomy of olfactory organs in some marine teleosts. *Zoologischer Anzeiger*, 5B: 441-444.
- Singh S.P., Singh S.B. (1989). A SEM study of the olfactory lamellae of the catfish *Heteropneustes fossilis* (Bl.). *Folia Morphologica*, 37: 407-409.
- Teichmann H. (1954). Vergleichende Untersuchungen an der Nase der Fische. *Zeitschrift Morphologica Ökol Tiere*, 43: 171-212.
- Theisen B. (1972). Ultrstructure of the olfactory epithelium in the Australian lungfish, *Neoceratodus forsteri*, *Acta Zoologica*, 53: 205-218.
- Uehara K., Miyoshi M., Miyoshi S. (1991). Cytoskeleton in microridges of the oral mucosal epithelium in the carp, (*Cyprinus carpio*). *Anatomical Record*, 230:164-168.
- Waryani B., Zhao Y., Zhang C., Dai R., Abbasi A.R. (2013). Anatomical studies of the olfactory epithelium of two cave fishes *Sinocyclocheilus jii* and *S. furcodorsalis* (Cypriniformes: Cyprinidae) from China. *Pakistan Journal of Zoology*, 45: 1091-1101.
- Yamamoto M., Ueda K. (1978). Comparative morphology of fish olfactory epithelium-III Cypriniformes. *Bulletin of the Japanese Society of Scientific Fisheries*, 44: 1201-1206.
- Yamamoto M. (1982). Comparative morphology of the peripheral olfactory organ in teleosts. In: T.J. Hara (Ed.). *Chemoreception in fishes*. Elsevier, Amsterdam. pp: 35-59.
- Zeiske E., Mellinkat R., Breucker H., Kux J. (1976). Ultrastructural studies on the epithelia of the olfactory organ of Cyprinodonts (Teleostei, Cyprinodontoidae). *Cell and Tissue Research*, 172: 245-267.
- Zeiske E., Theisen B., Breucker H. (1992). Structure, development and evolutionary aspects of the peripheral olfactory system. In: T.J. Hara (Ed.). *Fish chemoreception*. Chapman and Hall, London. pp: 13-39.
- Zeiske E., Theisen B., Breucker H. (1994). The olfactory organ of the hardhead sea catfish, *Arius felis* (L.): gross morphology and fine structure. *Acta Zoologica*, 75: 115-123.
- Zeiske E., Bartsch P., Hansen A. (2009). Early ontogeny of the olfactory organ in a basal actinopterygian fish: *Polypterus*. *Brain, Behavior and Evolution*, 73: 259-272.



چکیده فارسی

تجزیه و تحلیل ساختار بافتی و فراساختار اپیتلیوم بویایی ماهی *Puntius ticto* (Hamilton, 1822)

ساروج کومارگوش^{۱*}، باپادیتیا پان^۲، پادمانابها چاکرابارتی^۲

گروه جانورشناسی، آزمایشگاه شیلات، گروه جانورشناسی، دانشگاه بوردوان، بوردوان ۷۱۳۱۰۴، بنگال غربی، هندوستان.

مرکز ابزار دقیق علوم دانشگاه، دانشگاه بوردوان، بوردوان ۷۱۳۱۰۴، بنگال غربی، هندوستان.

مرکز ابزار دقیق علوم دانشگاه، دانشگاه بوردوان، بوردوان ۷۱۳۱۰۴، بنگال غربی، هندوستان.

چکیده:

ساختار سلول‌های پوشش مخاط بویایی گونه *Puntius ticto* (Hamilton, 1822) براساس مشاهدات میکروسکوپ‌های نوری و الکترونی رویشی توصیف گردید. جفت محفظه‌های بویایی در ناحیه قدامی-پشتی چشم واقع شده‌اند و از طریق منافذ قدامی و خلفی با بیرون در ارتباط می‌باشد. غنچه بویایی بیضی شکل در کف این محفظه قرار دارد و شامل ۲۰-۱۸ تیغه آرایش یافته در طرفین ستیغ میانی می‌باشد. نواحی حسی و غیرحسی به صورت مجزا در هر طرف تیغه‌ها پراکنش یافته‌اند و اپیتلیوم حسی به‌طور کلی بر دو نوع متمایز از لحاظ ریختی شامل سلول‌های گیرنده مژه‌دار و میکروویلی می‌باشد. اپیتلیوم غیرحسی شامل سلول‌های مژه‌دار غیرحسی، سلول‌های مطبق اپیتلیالی با ریزبرجستگی‌های متحدالمرکز و سلول‌های مخاطی می‌باشد. سلول‌های پایه در قسمت‌های عمیق‌تر اپیتلیوم، نزدیک هسته مرکزی واقع شده‌اند. در ادامه نیز اهمیت عملکردی اجزای سلولی اپیتلیوم بویایی در ارتباط با رفتار و زیستگاه گونه مورد مطالعه بحث شد.

کلمات کلیدی: اندام بویایی، آناتومی عملکردی، بافت شناسی، میکروسکوپ الکترونی رویشی.